

## Unusual presentation of follicular thyroid carcinoma as mandibular metastasis

Dave P.K.<sup>1</sup>, Puranik M.<sup>2</sup>, Jain M.<sup>3</sup>, Mishra R.<sup>4</sup>, Jain Singhai M.<sup>5</sup>, Lakra R.<sup>6</sup>, Rajak Y.<sup>7</sup>, Wandre A.<sup>8</sup>, Satpathy S.<sup>9</sup>, Gaur B.S.<sup>10</sup>

<sup>1</sup>Dr Pranav K Dave, Assistant Professor, <sup>2</sup>Dr. Puranik M, Assistant Professor, <sup>3</sup>Dr. Jain M, Professor, <sup>4</sup>Dr. Mishra R, Associate Professor, <sup>5</sup>Dr. Jain Singhai M, Assistant Professor, <sup>6</sup>Dr. Lakra R, Senior Resident, <sup>7</sup>Dr. Rajak Y, Junior Resident, <sup>8</sup>Wandre A, Senior Resident, Department of Radiodiagnosis, <sup>9</sup>Dr. Satpathy S, Assistant Professor, Department of Dentistry and oral surgery, <sup>10</sup>Dr. Gaur BS, Professor, Department of Pathology, all authors are affiliated with L.N. Medical College And J.K. Hospital, Bhopal, MP, India.

**Corresponding Author:** Dr. Monika Puranik, Assistant Professor, Department of Radiodiagnosis, L.N. Medical College and J.K. Hospital, Bhopal (MP). Email: monika\_bapat@yahoo.in

### Abstract

Primary carcinoma of thyroid presenting as mandibular metastasis is a rare incidence. Most of the time patient presents with various other symptoms due to hematogenous spread of primary neoplasm. We are presenting a rare case where metastatic lesion of mandible was the presenting feature and the patient was then subsequently diagnosed to have primary follicular carcinoma of thyroid.

**Key words:** follicular thyroid carcinoma, mandible, Metastasis.

### Introduction

Metastasis to oral region are less than 1% of neoplasm of all oral cancers, of which the mandible is the most common site [1]. These metastases may be the presenting feature without the diagnosis of primary neoplasm. Breast carcinoma in females and lung carcinoma in males are the most common primary

neoplasms to metastasize to mandible [2]. Mandibular metastasis from follicular thyroid carcinoma (FTC) is not very common and limited cases have been mentioned in the literature [3]. We present a rare case of FTC, presenting as mandibular metastasis.

### Case Report

A 71 years old male presented with swelling over left jaw and loosening of ipsilateral teeth since two months duration and was referred to our Department of Radiodiagnosis for OPG. Personal history revealed history of tobacco chewing for long time. On examination, a soft tissue swelling was seen over the left jaw. OPG revealed a large osteolytic lesion in the body of left half of mandible extending up to the vertical ramus, with soft tissue swelling and loss of adjacent teeth [Fig No.1]. Subsequent radiological work up revealed normal X Ray of chest.

Ultrasound of abdomen revealed cholelithiasis. CECT of head and neck was done to evaluate further and it revealed an expansile lytic vascular lesion in left ramus and body of mandible. It showed avid contrast enhancement [Fig No.2]. Left lobe of thyroid was found to be bulky & it had a heterogeneously enhancing nodular lesion with a speck of coarse calcification within [Fig. No. 3]. Incidental note was made of another lytic lesion in calvarium in occipital region [Fig No.4]. In view of vascular nature of lesion, additional lytic lesion in skull and a suspicious lesion in thyroid, possibility of primary thyroid malignancy with mandibular and calvarial metastases was raised. Subsequently ultrasound of left mandibular region revealed large soft tissue mass lesion with increased vascularity on colour Doppler. Ultrasound of thyroid revealed bulky left lobe having heterogeneous echotexture and scattered macro calcifications. No significant cervical lymphadenopathy was seen. X ray skull lateral view also revealed lytic lesion in occipital region.

Manuscript Received: 8<sup>th</sup> January 2018

Reviewed: 18<sup>th</sup> January 2018

Author Corrected: 24<sup>th</sup> January 2018

Accepted for Publication: 31<sup>st</sup> January 2018

## Case Report

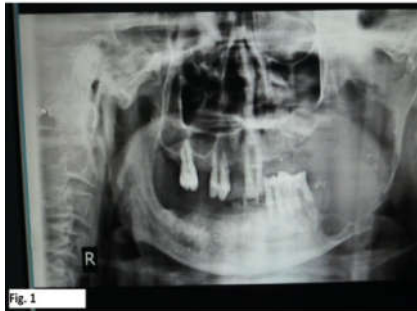


Fig. 1  
OPG - Large lytic lesion in body & ramus of mandible on left side

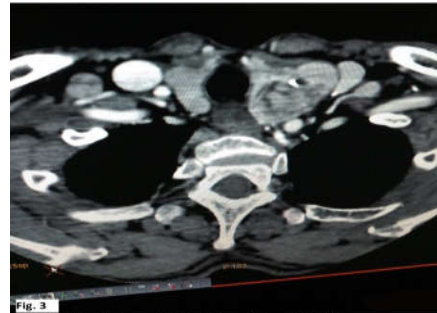


Fig. 3  
CT NECK : Enlarged left lobe of thyroid with heterogeneously enhancing mass lesion.

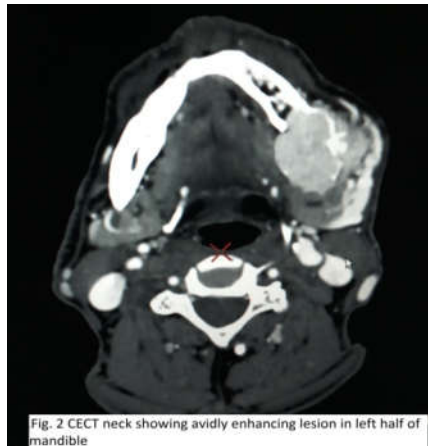

Fig. 2 CECT neck showing avidly enhancing lesion in left half of mandible

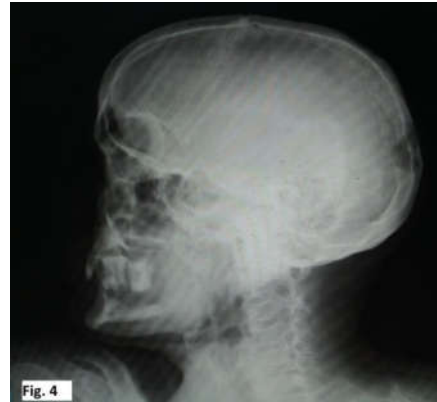

Fig. 4  
X RAY SKULL LATERAL VIEW: Lytic lesion in occipital region.

Ultrasound guided Fine needle aspiration cytology (FNAC) was performed from left mandibular lesion as well as lesion in left lobe of thyroid. Microscopic examination revealed features of follicular thyroid carcinoma (FTC) at both sites consistent with primary FTC with metastatic mandibular lesion. FNAC revealed - moderate cellularity with large number of follicular epithelial cells present predominantly in micro-follicles, few in large groups and crowded in syncytial sheets, few follicular cells show intra nuclear inclusion. Moderate degree of anisonucleosis, prominence of nuclei and irregularity of nuclear margin suggestive of follicular metastasis to the mandible and follicular carcinoma from left lobe of thyroid

## Discussion

Metastases to the oral region are around 1-3% of all malignancies [4]. The low incidence of metastases to oral cavity is attributed to the high tendency for the metastatic lesions going undetected, as micro-metastasis are rarely picked up on radiographs [11]. Moreover, mandible is not included in routine radiographic survey for metastatic work-up [2].

As per literature, in about 30% cases of patients with gnathic bone metastasis, the primary tumor remains asymptomatic and is not diagnosed at the time of presentation [5]. The literature states that there is a variable incidence of metastasis to mandible from different primary tumors, the common affected age group is 5<sup>th</sup> -7<sup>th</sup> decade [9]. Common primary tumors causing mandibular metastasis are lung, adrenal, kidney and thyroid in male and breast in female. However in younger population the metastasis is from adrenal,

neuroblastoma, medulloblastoma and osteogenic sarcoma [10]. Most of the mandibular metastatic lesions are osteolytic; however secondaries from prostate and breast are osteoblastic.

It has been suggested that the predilection of metastasis to body and ramus of mandible is due to rich blood supply [12]. Primary tumor may not be the presenting symptom and they tend to have hematogenous spread to lung and bone.

Mandibular metastasis from primary thyroid carcinoma are not very common. Thyroid carcinoma is the most frequently diagnosed endocrine carcinoma [7]. FTC is the second most common thyroid cancer after papillary carcinoma with incidence of 10%-20%. Papillary thyroid carcinoma is the commoner than follicular variety [7]. FTC affects elder population [5]. It shows

propensity to hematogenous dissemination to lung and bones in contrast to papillary carcinoma which usually remains localized to thyroid gland and shows predilection for lymph nodal metastases. FTC is less prone for lymphatic spread [6].

It causes unusual bone metastasis to skull, mandible, maxilla, spine and orbit. The presence of metastasis is an indicator of poor prognosis with decrease in survival period for the patient [8].

## Conclusion

True incidence of metastatic involvement of mandible is not very clear. High degree of suspicion and careful reading of the scan is necessary to detect primary malignancy.

The take home message is to ignore the obvious and keep in mind that metastases should be high on the list of differentials, particularly in elderly patients with mandibular lesions. Thorough search for primary should be made and thyroid lesion has to be ruled out.

**Conflict of interest:** None declared.

**Funding:** Nil, **Permission from IRB:** Yes

## References

1. Van der Waal RI Buter J. Oral Metastasis; Reoprt of 24 cases, Br J Oral Maxillofac Surg.2003;41:3-6.
2. Hirshberg A, Buchner A. Metastatic tumors to the oral region. An overview. Eur J Cancer B Oral Oncol. 1995 Nov; 31 B(6):355-60.
3. Ostrosky A, Mareso EA, Klurfan FJ, Gonzalez MJ. Mandibular metastasis of follicular thyroid carcinoma. Case report. Med Oral. 2003 May-Jul; 8 (3): 224-7.

## Case Report

4. C L, K R, M V. Mandibular metastasis of thyroid carcinoma: a case report. J Clin Diagn Res. 2014 Jul; 8 (7): ZD15-6. doi: 10.7860/JCDR/2014/9079.4588. Epub 2014 Jul 20.
5. Lindermann F, Schilmok G et.al. Prognostic significance of micro metastasis tumor cells in bone marrow of colorectal cancer patients. Lancet.1992: 340:685-9.
6. Naveen Kumar S. Metastasis of thyroid carcinoma to mandible- Journal of Chalmeda Anand Rao Institute Of Medical Sciences Vol 6 Issue 1 Nov 2013 73-77 .
7. Chetan J. Bhadage. Mandibular metastasis in a patient with follicular carcinoma thyroid. Contemp Clin Dent. 2012 Apr-Jun; 3(2): 212-214.
8. Muttagi SS, Chaturvedi P, D'Cruz A, Kane S, Chaukar D, Pai P, Singh B, Pawar P. Metastatic tumors to the jawbones: retrospective analysis from an Indian tertiary referral center. Indian J Cancer. 2011 Apr-Jun; 48 (2):234-9. doi: 10.4103/0019-509X.82894.
9. L Liu, G Venkataraman. Follicular variant of papillary thyroid carcinoma with unusual late metastasis to the mandible and the scapula. Pathol. Int., 57(5)2007.296-298
10. Kshitiz R. Thyroid carcinoma metastasizing in the mandible: A Case report; JISMA October – December 2011 Vol 24 number 4, 189-190.
11. Grebe SK, Hay ID. Follicular thyroid cancer. Endocrinol Metab Clin North Am. 1995 Dec; 24(4):761-801
12. Said Anajar. Mandibular metastasis revealed papillary thyroid carcinoma: Rare case. International Journal of Surgery Case Reports. Olume 37, 2017, 130-133

## How to cite this article?

Dave P.K, Puranik M, Jain M, Mishra R, Jain Singhai M, Lakra R, Rajak Y, Wandre A, Satpathy S, Gaur B.S. Unusual presentation of follicular thyroid carcinoma as mandibular metastasis. Surgical Update: *Int J surg Orthopedics*. 2018;4 (2): 68-70. doi:10.17511/ijoso.2018.i02.01.