

Comparison of PFN (Proximal femoral nail) and DHS (Dynamic hip screw) in treatment of Intertrochanteric femur fractures

Herode P.¹, Shroff A.², Sadaria M.³, Jeegar P.⁴

¹Dr. Prafulla Herode, Associate Professor, ²Dr. Abhijeet Shroff, Assistant Professor, D Y Patel Hospital and Medical College, Department of Orthopaedic, Pimpri, Pune, ³Dr. Mohan Sadaria, Senior Consultant and Orthopaedic Surgeon at Sadaria Orthopaedic Hospital, Surat, Gujarat, ⁴Dr. Patel Jeegar Mohan, Resident at D Y Patel Hospital and Medical College, Department of Orthopedic, Pimpri, Pune, Maharashtra, India.

Corresponding author: Dr. Abhijeet Shroff, Assistant Professor, D Y Patel Hospital and Medical College, Department of Orthopaedic, Pimpri, Pune. Email: drjmsadaria@gmail.com

Abstract

Introduction: Intertrochanteric femur fractures are common in the elderly people. The frequency of these fractures has increased primarily due to the increasing life span and more sedentary life style brought on by urbanization. The incidence of Intertrochanteric femur fractures is more in the female population compared to the male due to osteoporosis. **Aim and Objective-** To compare outcome of intertrochanteric femur fractures treated with DHS and PFN. **Methodology:** comparative study of proximal femoral nail and dynamic hip screw in the treatment of 50 cases of intertrochanteric femur fractures in the Department of orthopedics, DY Patil Hospital Pune was done from July 2015 to July 2016. **Result:** Result were almost similar in both groups. **Conclusion:** It is most difficult task to assess and decide as to which technique is better out the two. Some studies reveal DHS to be better than PFN, while some studies show vice versa. Both the techniques are precise, time tested & require reasonable amount of surgical skill. Final decision depends on operative surgeon's preference to specific technique.

Keywords: Proximal femoral Nail, Dynamic hip screw, Intertrochanteric femur fracture

Introduction

Intertrochanteric femur fractures are common in the old people. Incidence intertrochanteric femur fractures has been raised mainly because of increased in longevity and inactive life style due to advance technology. Cases of Intertrochanteric femur fractures is seen largely in females gender compared to counterpart because of more predisposition of female gender to osteoporosis.

Dynamic hip screw (DHS) or sliding hip screw (SHS) has been routinely use dim plant since long in treatment of Intertrochanteric fractures [1–5]. But, when comparing to intramedullary implants, its having biomechanical disadvantage of more space between the weight bearing axis and the implants [6]. The proximal femoral nail (PFN) introduced by the AO/ASIF group in 1998 is used increasingly to treat intertrochanteric fractures in recent period [7–10]. Thought here are many scientific surveys showing benefit of proximal femoral nail [12–14], however technical failures aren't

uncommon with PFN [15,16]. Cost-PFN is little costlier than DHS.

Aims

- To get stable reduction and fixation in same kind of fractures by using different internal fixation modalities of fixation: DHS and PFN
- comparison of outcome of intertrochanteric femur fractures treated by PFN and DHS in the management of Intertrochanteric femur fractures

Objectives

- To evaluate strength and stability of PFN and DHS in the fixation of trochanteric fractures.
- To compare effectiveness of proximal femoral nail and Dynamic hip screw regarding early mobilization of the patients

Evans Classification
Evans type I

Manuscript Received: 15th December 2017
Reviewed: 24th December 2017
Author Corrected: 30th December 2017
Accepted for Publication: 5th January 2018

Original Research Article

Fracture line extending upward and outwards from lesser trochanter.

Evans type II

Reverse oblique fracture, major fracture line extends outwards and down wards from lesser trochanter. These type II fractures have tendency towards medial displacement of femoral shaft due to pull of adductor muscles.

Methodology

This comparative study 50 cases of DHS vs PFN in treatment of intertrochanteric femur fractures was performed at Padmshree Dr D Y Patil medical college and hospital, Pimpri, Pune, and functional outcome was compared in both; DHS and PFN groups with evaluation of postoperative range of movements by Harris hip score.

Choice of Nail Used- Hollow tubular proximal femoral Nail was used which was made up of AISI 316 L stainless steel. In current research study we utilized nails of same length of 25 mm in all 25 cases. Diameter of proximal portion of nail is 17 mm (proximal 8 cm of nail) and the distal part varying from 9 to 12 mm. Proximal femoral nail ranging from 130 & 135 degree with 10 degree of ante version was used in this study. Antero-posterior radius of this proximal femoral nail is 3000 mm in and 4 degree curve towards lateral. Proximal portion of the nail has slot for fixation for two screws, size of the lag screw 7.9 mm with availability ranging from 55 mm to 115 mm. Proximal one (P1) is of size 6.4 mm and its available in varying lengths ranging from 55mm to 115mm. This is the one which controls the rotation and also known as ANTI ROTATION SCREW. In view of preventing growth in the proximal part of the nail threaded cap is available. To fix distal screws in PFN distal part has two holes. Of these two proximal holes first one also known as derotation screw is for static locking and proximal second screw is for dynamic fixation.

Nail Length Measurement- Our study consisted of use of nails of same size length nail i.e 25 mm in all cases.




Figure-1: Proximal Femoral Nail

Measuring diameter of the nail- Uninvolved side femur radiograph was taken & diameter of canal at the isthmus between both cortexes was measured. We also took help of the ruler provision from the PACS system of x rays which is used in our hospital. By this technique direct measurement of diameter of bone can be made on the computer monitor. However, nails of all sizes were kept ready for operation i.e 9 mm to 12 mm size.




Figure-2: Sliding Plate with Richard Compression Screw

Original Research Article

Richards dynamic compression screw- Consisting of cannulated lag screw from 19 mm or 29 mm threaded distal portion of 12.7 mm diameter and a proximal no threaded portion (shaft) of 8.7 mm diameter. Richard screw comes in different lengths measuring from 50-110 mm. A 3.2 mm guide wire is used from which Richard screw can be passed. The lag screw is inserted into bone passing through barrel at which it can slide.

There is groove along with length of Richard screw, which guides direction of key in the barrel. This prevents the rotation. The side plate was available in 2-20 holes, which accommodate 4.5 mm cortical bone screws. Usually 4 or 5-hole plate were used.

Observations and Results

The following observations were made from the data collected during this Comparison of PFN and DHS in treatment of intertrochanteric femur fractures of 50 cases in the Department of Orthopedics, DY Patil Hospital Pune, from July 2015 to July 2016.

There was almost similar involvement of both genders with maximum patients between 56-60 of age (24%). there was no systemic infection in any group, while 1 patient in each group had UTI and chest infection postoperatively. Limb shortening incidence was more (3(12%)] patient in DHS group compared to PFN group [1(4%)] patients, none of group had deep infection except 1 case of superficial infection in PFN group and 2 in PFN group. external rotation was noticed in PFN group in 1 patient. varus deformity was more common in DHS group (2 cases) compared to PFN group (1 group).

Table-1: Distribution of implant according different age group

Age(Year)	No.of patients in PFN	No.of patients in DHS
20-30	3(12%)	2(8%)
30-40	2(8%)	2(8%)
40-50	3(12%)	3(12%)
50-60	6 (24%)	6(24%)
60-70	5(20%)	5(20%)
70-80	5(20%)	6(24%)
80-90	1(4%)	1(4%)
Total	25	25

Table-2: Post-operative complications

Complications	No.of patients PFN	No.of Patients in DHS
System complications	0	0
Chest infection	1(4%)	1(4%)
Pulmonary embolism	0	0
Shortening	01(4%)	3(12%)
Urinary tract infection	1(4%)	1(4%)
Urinary retention	0	0
Deep vein thrombosis	0	0
Local complication	0	0
Superficial wound infection	1(4%)	2(8%)
Deep wound infection	0	0
Death	0	0

Table-3: Rotational Malalignment

Rotational malalignment	No.of Patients in PFN	No.of Patients in DHS
External rotation	01(4%)	0
Internal rotation	0	0
Varus deformity of hip	01(4%)	2(8%)
Valgus deformity	0	0
Shortening	01(4%)	3(12%)

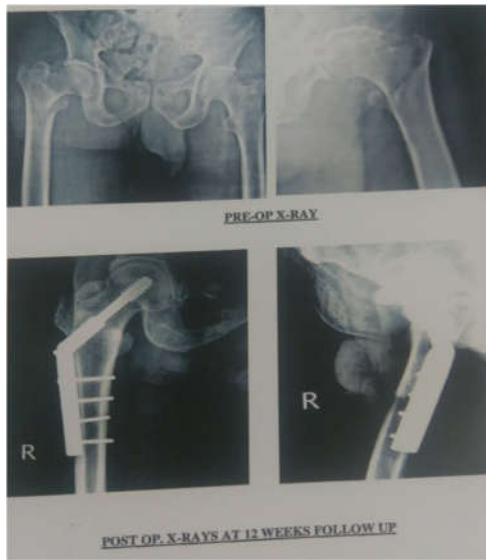

Table 3 Pre op and Post op x-ray with PFN

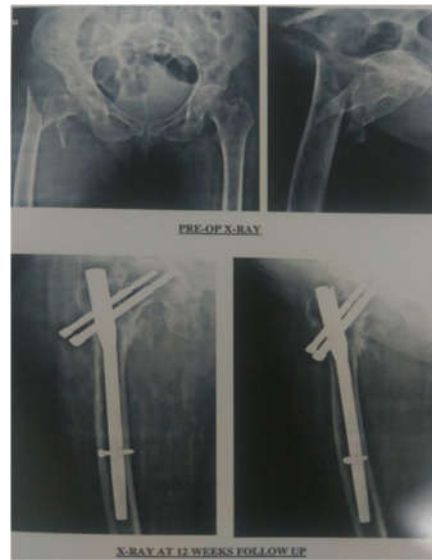

Table 3 Pre op and Post op x-ray with DHS

Table-4: Hip range of motion (Calculated by Harris Hip Score)

Range of Motion	PFN				DHS			
	Excellent	Good	Fair	Poor	Excellent	Good	Fair Poor	Poor
Flexion	6(25%)	10(50%)	3(15%)	1(5%)	6(25%)	10(50%)	3(15%) 2(10%)	1(5%)
Abduction	4(20%)	10(50%)	4(20%)	2(10%)	4(20%)	10(50%)	4(20%) 1(5%)	2(10%)
External rotation	4(20%)	10(50%)	4(20%)	2(10%)	4(20%)	10(50%)	4(20%) 2(10%)	2(10%)
Internal rotation	4(20%)	10(50%)	4(20%)	2(10%)	4(20%)	10(50%)	4(20%) 1(5%)	2(10%)

Discussion

Intertrochanteric femur treatment is challenging fracture by the orthopedic community, not for fixation only, but also for restoration of optimum alignment and function earliest minimizing complications. Surgical fixation permits early rehabilitation and better functional recovery compared to conservative.

Most of patients in present study were from age group of 5th to 7th decade of life. Gallagher et al (1980) reported an eight fold increase in intertrochanteric fractures in men over 80 years and women over 50 years of age [17].

Its because of trochanteric region is the most common site of senile osteoporosis. As hip joint is major weight bearing joint; it gets weak due to continuous abnormal stress of body and trabecular space is enlarged and loaded with fat, and calcaris atrophied.

Table-5: Average age reported by other workers is as follows.

Name of the worker	Age in years
Cleave land and Thompson, 1947	76.0
MurrayandFrew,1949	62.5
BoydandGriffin,1949	69.7
Scott, 1951	73.3
Evans1951- Males	62.6
Females	74.3
Wade and Campbell (1959)	72.0
Sarmiento,1963	71.9
Gupta, RC, 1974	51.2

Males to female ratio was 2:1 in both the groups. Higher incidence of trochanteric fractures in males were due to their more active lifestyles. David G. Lovelle found trochanteric fractures more common in women than men by a margin of three to one. Melton J.L., Ilistrup DM, Riggs BL et al reported a female to male ratio of 1.8:1 [18]. Helfenste in (1947) suggested that, by stimulation of osteoclasts due to post-menopausal deficiency of steroid hormone sis responsible for greater osteoporosis. St. Urnier K.M., Dresing K (1995) suggested that pertrochanteric fractures ordinarily appears to women 10-15 years later than to men [19]. H. B. Boyd and L. L. Griffin in their study of 300 cases found a marked sex difference. 226 (75.8%) of the patients were females and 74 (24.2%) were males [20].

Most of our patients were 50 years and above in them domestic fall (fall at home) and trivial trauma was main reason behind fracture while in road traffic accident (RTA) young patients were affected. This may be attributed to the following factors as enumerated by Cummings and Nevitt in 1994 [21]. Inadequate protective reflexes, to reduce energy off all below a certain critical threshold. Inadequate local shock absorbers e.g. muscle and fat around hip. Inadequate bone strength at the hip on account of osteoporosis or osteomalacia. Horn & Wang stated that mechanism of injury is not direct but due to failure of Stress resisting forces during sudden bending or twisting. A direct blow on the lateral side of thigh would result in contusion, comminution on the lateral surface of the greater trochanter and cause valgus deformity [22].

External rotation of 15° was noticed in one case operated by proximal femoral nail (PFN) and varus deformity was noted in one case. It might be seen due to early backing out of screws. In 2 cases of varus deformity was seen in the cases operated by DHS. Due to the pull of the muscle the distal shaft fragment has the tendency to migrate upwards thus result in gin varus deformity. In the series by K.D Harrington, out of 72 cases there were 4 cases of coxa vara and 56 cases of limb shortening at an average of 1.5 cms [23].

In his series, shortening was noted in unstable fractures in which Dimon Hughston procedure was done. In the series by Juluru P. Rao of the 124 cases of intertrochanteric fractures, 5 cases of unstable fracture had limb shortening [24].

Average admission time was 21 days (3 Weeks). According to post-operative pain and general condition patients were made to stand up with walker on 4-5th post-operative day. And then gradually non-weight bearing walking was started within 2-3 days with Walker. In study by B. Mall (30 patients) average ambulation time was 14 days. In the series of Dr. G.S Kulkarni ambulation was usually started after 11-12 days after the stitch removal [25,26].

Average time of union in all our 50 patients was about 16 weeks Assessment of early call us formation at fracture site & its subsequent progress was done with the help of ultrasonography in few cases [27, 28]. This was perform ed at subsequent interval of 14th & 28th post-operative days. Neo vascularization & soft call us in early phases & consolidation of call us was noted in follow up ultrasonographic study.

Table-6: Radiological time of union in other series

Sr.No.	Series	Radiological union (in weeks)
1	KevinD. Harrington [29]	16
2	Juluru- P. Rao [24]	18
3	Luis A. Flores [30]	13
4	B. Mall [31]	14
5	Present Series	16

The patient who was operated by PFN had infection at distal site of suture line. While 2 cases operated by DHS had superficial wound infection at the suture site. It may be because of nutritional deficit and low socio-economic status of patient & mores of tissue exposure, which is more in cases operated by DHS. In the series of patients operated by DHS by Dr.G.S Kulkarni, there were two cases of deep infections which were treated by removal of implant. The infected sinuses thus healed after implant removal. There were 3 cases (15%) of shortening seen in the cases operated by DHS. This shortening ranged from 1-1.5 cms. Patients were given shoe raise which compensated for the necessary shortening. Patients did not have any difficulty later while walking. In the series by Juluru P. Rao of the 124 cases of intertrochanteric fractures, 5 cases of unstable fracture had limb shortening [24].

The range of movement calculated by the Harris Hip Scoring system treated by both the implants i.e PFN and DHS was good and was almost the same. The range of movements namely flexion, extension, external and internal rotation was good in most cases. The poor result was attributed to associated factors namely along interval between trauma and surgery & development of post operative infection. These fractures are more commonly seen in elderly people particularly in 5th to 7th decades of life [32,33]. Common mechanism of injury is trivial trauma due to fall [14], however in younger patients they are seen. These fractures are more commonly seen in elderly people particularly in 5th to 7th decades of life [32,33]. Common mechanism of injury is trivial trauma due to fall [34], however in younger patients they are seen following high energy trauma like Road traffic accident (RTA), fall from height etc. In older patients apart from osteoporosis as major risk factor, anemia, cachexia, cognitive dysfunction, visual impairment, social dependence are some other factors which makes these people more prone for such fractures [35].

Conclusion

It is very difficult to do assessment and conclude that one is better type of fixative technique. Some studies shows DHS to be better than PFN, while other studies shows PFN better. Both fixative methods are accurate, tested & needs good surgical skill. There is no much difference in complications in these two techniques. Choice of implant depends on age, type of fracture and economic status of patient. It takes long to learn PFN technique compared to DHS for a surgeon, to be comfortable with that technique. Lastly it is up to operating surgeon's choice what to use PFN or DHS. If operating surgeon is used to do with any of these two, he will get satisfactory results.

What this study add to existing knowledge?

It is not only instrumentation but experience of surgeon with that instrumentation technique that helps in fixation of fracture that can be treated with various option and one should always prefer instrumentation he/she is used to with.

Conflict of interest: None declared.

Funding: Nil, **Permission from IRB:** Yes

References

- Butt MS, Krikler SJ, Nafie S, Ali MS, Comparison of dynamic hip screw and gamma nail: a prospective, randomized, controlled trial. *Injury*. 1995 Nov; 26(9):615-8.
- Bridle SH, Patel AD, Bircher M, Calvert PT. Fixation of intertrochanteric fractures of the femur. A randomised prospective comparison of the gamma nail and the dynamic hip screw. *J Bone Joint Surg Br*. 1991 Mar;73(2):330-4.
- Goldhagen PR, O'Connor DR, Schwarze D, Schwartz E. A prospective comparative study of the compression hip screw and the gamma nail. *J Orthop Trauma*. 1994 Oct;8(5):367-72.
- Hoffman, C. W. and Lynskey, T. G. Intertrochanteric Fractures Of The Femur: A Randomized Prospective Comparison Of The Gamma Nail And The Ambl Hip Screw. *Australian and New Zealand Journal of Surgery*, 1996;66: 151–155. doi:10.1111/j.1445-2197.1996.tb01144.x

Original Research Article

5. Radford PJ, Needoff M, Webb JK. A prospective randomised comparison of the dynamic hip screw and the gamma locking nail. *J BoneJointSurg Br.* 1993 Sep;75(5):789-93.
6. Parker MJ, Handoll HHG. Gamma and other cephalocondylic intramedullary nails versus extramedullary implants for extracapsular hip fractures in adults. *Cochrane Database of Systematic Reviews* 2010, Issue 9. Art. No.: CD00-0093. DOI: 10.1002/14651858. CD000093. pub5.
7. J. Anand, *The Elements of Fracture Fixation*, Churchill Livingstone, New York, NY, USA, 1997.
8. Banan H, Al-Sabti A, Jimulia T, Hart AJ. The treatment of unstable, extra capsular hip fractures with the AO/ASIF proximal femoral nail (PFN)-our first 60 cases. *Injury.* 2002 Jun;33(5):401-5.
9. Banan H, Al-Sabti A, Jimulia T, Hart AJ. The treatment of unstable, extracapsular hip fractures with the AO/ASIF proximal femoral nail (PFN)--our first 60 cases.
10. Al-yassari G, Langstaff RJ, Jones JW, Al-Lami M. The AO/ASIF proximal femoral nail (PFN) for the treatment of unstable trochanteric femoral fracture, *Injury.* 2002 Jun;33(5):395-9.
11. Gadegone WM, Salphale YS. Proximal femoral nail - an analysis of 100 cases of proximal femoral fractures with an average follow up of 1 year. *Int Orthop.* 2007 Jun;31(3):403-8. Epub 2006 Jun 21.
12. Nuber S, Schönweiss T, Rüter A. [Stabilisation of unstable trochanteric femoral fractures. Dynamic hip screw (DHS) with trochanteric stabilisation plate vs. proximal femur nail (PFN)]. *Unfallchirurg.* 2003 Jan;106(1):39-47.
13. Z.Y.Huang, X.W.Liu, and J.C.Su. Dynamic hip screw vs. Proximal femur nail in treatment of intertrochanteric fractures in patients aged over 70 years old. *Shanghai Medical Journal*, 2010;vol.33, no. 11,1042
14. Pajarinen, J., Lindahl, J., Michelsson, O., Savolainen, V., & Hirvensalo, E. Petrochanteric femoral fractures treated with a dynamic hip screw or a proximal femoral nail. *Bone & Joint Journal*, 2005; 87-B(1), 76-81. Accessed November 18, 2017. [https:// doi.org/10.1302/0301-620X.87B1.15249](https://doi.org/10.1302/0301-620X.87B1.15249).
15. R.E.S. Pires, E.O.Santana, L.E.N. Santos, V. Giordano, D. Balbachevsky and F.B.dos Reis. Failure of fixation of trochanteric femur fractures: clinical recommendations for avoiding Z-effect and reverse Z-effect type complications. *Patient Safety in Surgery*, vol.5, no.1, article 17, pp.1-6, 22 June 2011.
16. Pavelka T, Matejka J, Cervenkova H. [Complications of internal fixation by a short proximal femoral nail] *Acta ChirOrthopTraumatol Cech.* 2005;72(6) 344-354.
17. Gallangher J C, Melton L J, Riggs B Let al. Epidemiology of fractures of the proximal femur in Rochester, Minnesota. *Clinical Orthop* 1980;150: 163-171.
18. Heinz T, Vécsei V. [Complications and errors in use of the gamma nail. Causes and prevention]. *Chirurg.* 1994 Nov;65(11):943-52.
19. Griffin JB. The calcar femorale redefined. *ClinOrthopRelat Res.* 1982 Apr;(164):211-4.
20. Cummings SR, Nevitt MC. Non-skeletal determinants of fractures: the potential importance of the mechanics of falls. Study of Osteoporotic Fractures Research Group. *OsteoporosInt.* 1994;4 Suppl 1:67-70.
21. Dean, G. L., S. David, and H. N. Jason. Osteoporotic petrochanteric fractures; management and concurrent controversies. *J Bone JtSurg (Am)* 2004;72: 737-752.
22. Kevin D. Harington, San Francisco, James O, Jhoston. The management of comminuted unstable intertrochanteric fractures. *JBJS* 55A, no 7, 1367-76, Oct, 1973.
23. Rao, Juluru P, Banzon, Manuel T, Weiss, Andrew B, Rayhack, John, Treatment of unstable intertrochanteric fracture with anatomic reduction and compression hip screw. *ClinOrthop and related research*, No. 175, 65- 78 May 1983.
24. Pathak SK, Mehrotra V, Mall B. Role Of Dynamic Compression HIP Screw In Trochanteric Fractures Of Femur. *Indian Journal of Orthopaedics.* 1999 Jul 1;33(3):226.
25. Kulkarni GS: Treatment of trochanteric fractures of hip by modified Richard's compression and

Original Research Article

- collapsing screw, Indian Journal of Orthopedics, vol. 18, No. 1,30,1984.
26. Windoff j, Hollander D A ,Hakmi M , Linhart w 2005, Pitfalls & complications in the use of proximal femoral nail, Lagenbecks arch surg, feb; 3901(1) Epub 2004 Apr 15.
27. Domingo LJ, Cecilia D, Herrera A, Resines C. Trochanteric fractures treated with a proximal femoral nail. *IntOrthop*. 2001;25(5):298-301.
28. Frigg R, Appenzeller A, Christensen R, Frenk A, Gilbert S, Schavan R The development of the distal femur less invasive stabilization system (LISS). *Injury* 2001; 32Suppl3:SC24-S'C31.
29. AlbaredaJ, LaderigaA, Palanca Detal Complications and technical problems with the gamma nail. *Int Orthop*; 1996;20 :47-50.
30. Babhulkar Sudhir S. Management of trochanteric Fractures. *Indian Journal Of Orthopedics*; 2006;40 (10):210-218.
31. Banan H, Al-Sabti A, Jimulia T, Hart AJ. The treatment of unstable, extracapsular hip fractures with the AO/ASIF proximal femoral nail (PFN)--our first 60 cases. *Injury*. 2002 Jun;33(5):401-5.
32. Schipper IB, BresinaS, Wahl D, Linke B, Van Vugt AB, Schneider E. Biomechanical evaluation of the proximal femoral nail. *Clin Orthop Relat Res*. 2002 Dec; (405):277-86.
33. Al-yassari G, Langstaff RJ, Jones JW, Al-Lami M. The AO/ASIF proximal femoral nail (PFN) for the treatment of unstable trochanteric femoral fracture. *Injury*. 2002 Jun;33(5):395-9.

.....

How to cite this article?

Herode P, Shroff A, Sadaria M, Jeegar P. Comparison of PFN (Proximal femoral nail) and DHS (Dynamic hip screw) in treatment of Intertrochanteric femur fractures. *Surgical Update: Int J surg Orthopedics*.2018;4(1):37-44.doi:10.17511/ijoso.2018.i01.07.

.....