

Familial Meckel's diverticulum - still a mystery. A retrospective case series in a tertiary care centre in South India

George R.¹, Thomas V.², Sasidharan B.³, Jojo J.^{4*}

DOI: DOI: <https://doi.org/10.17511/ijoso.2021.i05.06>

¹ Rahul George, MBBS, MS, Assistant Professor, Department of General Surgery, MOSC Medical College and Hospital, Kolenchery, Ernakulam, Kerala, India.


² Vijy Paul Thomas, MS, MRCSEd, Professor & HOD, Department of General Surgery, MOSC Medical College and Hospital, Kolenchery, Ernakulam, Kerala, India.

³ Beauty Sasidharan, MBBS, DLO, Junior Resident, Department of General Surgery, MOSC Medical College and Hospital, Kolenchery, Ernakulam, Kerala, India.

^{4*} Joicy Els Jojo, MBBS, Junior Resident, Department of General Surgery, MOSC Medical College and Hospital, Kolenchery, Ernakulam, Kerala, India.

Meckel's diverticulum is the most frequent congenital malformation of the gastrointestinal tract. Though a congenital abnormality, it rarely requires surgery. Although, there is no definite probability of familial predisposition, a few cases occurring within the same family have been reported. Retrospective case series of 2 siblings with incidentally detected Meckel's diverticulum with appendicitis. Conclusion: There exists the probability of familial predisposition of Meckel's diverticulum. Careful consideration should be made in siblings or relatives of a previously diagnosed Meckel's diverticulum. Early exploration should be done to prevent morbidity and mortality associated with late complications.

Keywords: Meckel's Diverticulum, Familial, Congenital, Complications

Corresponding Author	How to Cite this Article	To Browse
Joicy Els Jojo, MBBS, Junior Resident, Department of General Surgery, MOSC Medical College and Hospital, Kolenchery, Ernakulam, Kerala, India. Email: joicy94@gmail.com	Rahul George, Vijy Paul Thomas, Beauty Sasidharan, Joicy Els Jojo, Familial Meckel's diverticulum - still a mystery. A retrospective case series in a tertiary care centre in South India. <i>Surgical Rev Int J Surg Trauma Orthoped.</i> 2021;7(5):130-136. Available From https://surgical.medresearch.in/index.php/ijoso/article/view/238	

Manuscript Received
2021-07-03

Review Round 1
2021-07-05

Review Round 2
2021-07-12

Review Round 3
2021-07-19

Accepted
2021-07-25

Conflict of Interest
Nil

Funding
NIL

Ethical Approval
Yes

Plagiarism X-checker
16%

Note



© 2021 by Rahul George, Vijy Paul Thomas, Beauty Sasidharan, Joicy Els Jojo and Published by Siddharth Health Research and Social Welfare Society. This is an Open Access article licensed under a Creative Commons Attribution 4.0 International License <https://creativecommons.org/licenses/by/4.0/> unported [CC BY 4.0].



Introduction

Meckel's diverticulum, a remnant of the omphalomesenteric duct is the most frequent congenital malformation of the gastrointestinal tract. It is identified in 0.3–2.9% of the general population [1]. It is a true diverticulum that contains all layers of the intestinal wall and is identified as a saccular, blind-ending structure located on the antimesenteric border of the distal ileum. Meckel's diverticulum though noted to be a congenital abnormality, is noted rarely during life nor does it cause symptoms requiring surgery. Meckel's diverticulum is identified either in the context of the development of complications or as an incidental finding during exploratory laparotomy [2, 3]. The incidence of familial Meckel's diverticulum is 1/2500 cases according to Matsukuma *et al* [4]. Meckel's diverticulum was seen to have a familial occurrence only in 15 cases as per the literature published between 1955 and 1994, however, complications related to Meckel's diverticulum was the presenting symptom only in 5 of these [4-6]. A recently published article by Patoulias *et al* in 2020 reported 3 first degree relatives who presented with complications of Meckel's diverticulum. Though there is no documented evidence of familial predisposition of Meckel's diverticulum, there have been reports of Meckel's diverticulum occurring in family members based on current knowledge [1]. After a systematic and comprehensive review of the relevant literature concerning the familial occurrence of Meckel's diverticulum in specific and omphalomesenteric duct remnants in general, we observed the extreme rarity of the presented case. Herein, we present 2 cases of Meckel's diverticulum affecting siblings (brother and sister) who were managed in a tertiary care centre (academic institution) in South India.

Case Study

Case 1 - 17-year-old gentleman, presented to the emergency room, referred from a local hospital with complaints of fever, abdominal pain, and multiple episodes of vomiting and loose stools of 2 days duration. On examination, the patient was conscious and cooperative with no pallor. There was tenderness in the periumbilical region with guarding and rebound tenderness in the right iliac fossa. Ultrasound of the abdomen showed a non-compressible peristaltic blind-ending

Tubular structure of maximum calibre 6.5 mm with adjacent multiple enlarged mesenteric lymph nodes largest measuring 12mm in short axis and no adjacent free fluid. He was taken up for emergency laparoscopic surgery under general anaesthesia. 10mm sub umbilical, 5mm suprapubic and 5mm left iliac fossa ports were used. The open technique of pneumoperitoneum was done.

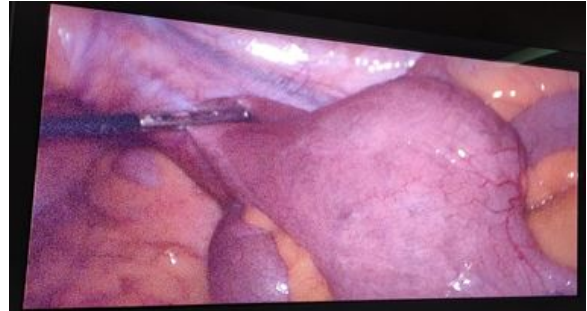


Figure 1: Laparoscopic view of Meckel's.

The appendix was inflamed with pus and omental adhesions. A sessile inflamed Meckel's diverticulum was found 50 cms proximal to the ileocecal junction with a mesodiverticular band extending to its tip (Figure 1). Resection was planned as the diverticulum bled on touch. He underwent laparoscopic appendicectomy with segmental ileal resection via extended sub umbilical incision with end to end anastomosis in 2 layers (Figure 2).

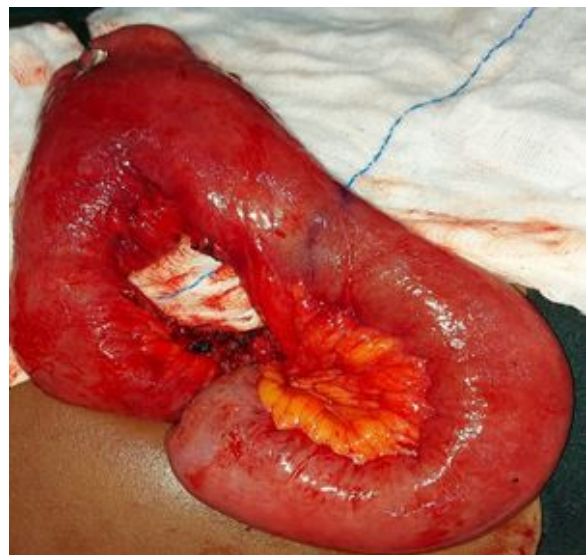

Figure 2: Segment of bowel containing Meckel's Diverticulum being resected.

Histopathology was reported as Acute Suppurative Appendicitis with Meckel's diverticulum showing florid lymphoid hyperplasia (Figure 3).

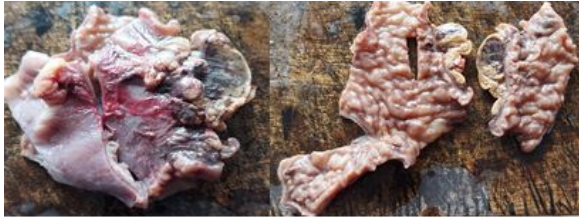

Figure 3: Gross specimen of resected Meckel's Diverticulum.

Case 2 - 24-year-old lady, sister of the previously mentioned patient, presented to the emergency room with abdominal pain and nausea of 1-day duration. On physical examination, she was hemodynamically stable with no pallor. The abdomen was soft with tenderness in the right iliac fossa. Contrast-enhanced CT scan of the abdomen revealed mildly dilated appendix 7mm in diameter, periappendiceal fat stranding and peritoneal thickening with few prominent mesenteric lymph nodes and left ovarian dermoid cyst. She was posted for emergency diagnostic laparoscopy under general anesthesia. 10 mm sub umbilical, 5mm suprapubic and 5mm left iliac fossa ports were used. The open technique of pneumoperitoneum was done. The appendix was inflamed with minimal pus in the pelvis. Meckel's diverticulum was noted 40 cms proximal to the ileocecal junction with a mesodiverticular band entering its tip (Figure 4). She underwent laparoscopic appendectomy, segmental ileal resection with end to end anastomosis in 2 layers along with excision of the ovarian dermoid cyst via extended sub umbilical incision.

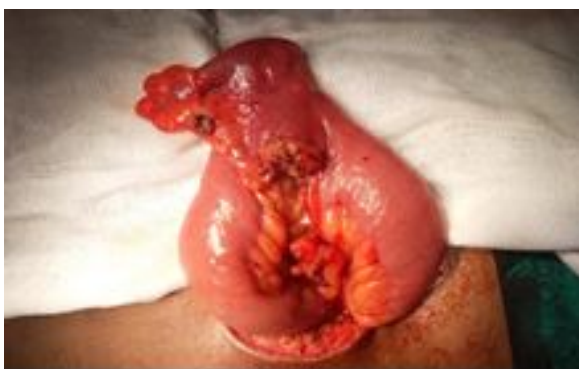

Figure 4: Segment of bowel containing Meckel's Diverticulum being resected.

Histopathology was reported as acute appendicitis with a specimen of diverticulum showing histological features consistent with Meckel's diverticulum with features of lymphoid hyperplasia

(Figure5). Specimen of the left ovarian cystic mass showed cyst wall lined by stratified squamous epithelium with adnexal structures. Both patients were followed up in the outpatient department after 2 weeks and noted to be in good health with no postoperative complications.



Figure 5: Gross specimen of Meckel's Diverticulum.

Discussion

Fadricius Hildamus first mentioned Meckel's diverticulum in 1598 [7]. The embryological and pathological characteristics of Meckel's diverticulum was published in an article in 1809 by German anatomist Johann Friedrich Meckel, which was later named after him [8]. The identification of the presence of ectopic mucosa of the stomach by Salzer and the finding of ulceration of ileum by Deetz increased the understanding of Meckel's diverticulum [1]. Meckel's diverticulum is lined by the typical ileal mucosa, but approximately 60% of Meckel's diverticula contain heterotopic mucosa at the tip, of which 60% contains mucosa of the stomach [9]. Meckel's diverticulum is symptomatic only in 2% of cases. It is twice more common in males than females [10]. Clinical presentation of Meckel's diverticulum is usually very silent but can be incidental or present with complications of gastrointestinal bleeding or with acute abdomen [8,11-13]. Gastrointestinal bleeding is the most common clinical presentation. Another common complication that can present is, intestinal obstruction, as a result of a volvulus/torsion of the small bowel around a diverticulum associated with a fibrotic band attached to the abdominal wall, intussusception or rarely, incarceration of the diverticulum in an inguinal hernia (Littre's hernia) and perforation—spontaneously or by the foreign body [14-17]. Tumours were found in 0.5 to 3.2 percent of Meckel's diverticulum [18-20]. Lipomas, leiomyomas and angiomas were the majority of benign tumours reported, however rare malignancies reported within Meckel's diverticulum are Carcinoid tumour, intraductal papillary

Mucinous adenoma of the pancreas, adenocarcinoma and gastrointestinal stromal tumours [21-27]. The preoperative diagnosis of Meckel's diverticulum may be difficult and is still an outstanding challenge—we do often come across cases that are misdiagnosed or not diagnosed preoperatively. The diagnosis of Meckel's is an enigma as the features on imaging and patients symptoms are non-specific [28,29]. Plain abdominal radiography, CT and ultrasonography are rarely helpful [30]. In children, the single most accurate diagnostic test is scintigraphy with sodium ^{99m}Tc pertechnetate (Meckel's scan). The preferred modality in complicated and suspected cases is diagnostic laparoscopy [31]. Surgical intervention is the treatment of choice for symptomatic Meckel's diverticulum which is achieved either by the resection of the diverticulum or by the segmental bowel resection and anastomosis. The anastomosis can be performed using a hand-sewn technique or a stapler across the base of the diverticulum [31-33]. There is an ongoing debate whether to excise Meckel's diverticulum when found as an asymptomatic incidental finding. Most authors favor prophylactic diverticulectomy while few are against it due to the associated postoperative morbidity. It is often not possible at the time of intervention, to determine whether Meckel's diverticulum found incidentally is at increased risk of complications or not. The risk factors for an incidental Meckel's diverticulum to become complicated, which were suggested significant by Mackey and Dineen were males less than 40 years and Meckel's that were 2 centimetres long containing ectopic mucosa [34]. Removal of symptomatic and asymptomatic Meckel's diverticulum was recommended in children younger than 8 years by Onenet al [35]. Male gender, an individual whose age is less than 45 years, fibrous band and length longer than 2 centimetres were considered in the risk assessment tool by Robijn et al in 2006 [36]. It was proposed by Ueberrueck et al, that in case of gangrenous or perforated appendicitis, an incidentally detected Meckel's diverticulum should not be resected [37]. Incidentally seen Meckel's in asymptomatic women were not recommended for removal by Stone et al [23]. The role of prophylactic diverticulectomy for incidentally detected Meckel's remains controversial. The morbidity and mortality are high when complications arise from a Meckel's diverticulum. Resection of incidental Meckel's diverticulum has a lower postoperative complication, lower morbidity

And mortality rate as compared to resection of a complicated Meckel's diverticulum as described by Cullen et al, who announced a lifetime risk of 6.4% for the development of complications in Meckel's diverticulum [38]. Although, there is no definite probability of familial predisposition of Meckel's diverticulum, a few cases of occurrence has been reported within the same family [39]. A report was published in 1955 [40]. The earliest found talks of a family which presented 4 cases of which one was gangrenous diverticulitis. The second report also in the same year, describes a patient with a peptic ulcer in a Meckel's diverticulum which had haemorrhaged and his brother who had a perforated Meckel's diverticulum [41]. 4 years later in 1959, there was a third report of a patient with perforated gangrenous diverticulum whose sibling was also found to have Meckel's diverticulum [42]. In 1963, 4 cases were reported in a single family of which one was complicated and the others were incidentally detected [6]. In 1994, a case of siblings with Meckel's diverticulum diagnosed before surgery was noted [4]. Complications in Meckel's diverticulum was seen in 3 first degree relatives in a journal published in 2020 [43].

Conclusion

Studies in future should focus on the genetic background of familial Meckel's diverticulum. Careful consideration should be made for a presymptomatic diagnosis of Meckel's diverticulum in a sibling or a relative of a previously diagnosed Meckel's diverticulum. Complications of Meckel's should be kept in mind as a differential diagnosis for every pediatric and adult patient who presents with acute abdomen. With the increasing use of laparoscopy, morbidity and mortality associated with the excision of Meckel's diverticulum have shown a significant decline.

Acknowledgements: I would like to extend my sincere gratitude to Dr Vijy Paul Thomas for his guidance in managing the patients and in every step of the research. Dr Beauty Sasidharan for their technical assistance, Dr Beena Mary Thomas and Dr Varughese George for prompt histopathology reports and Dr Joicy Els Jojo for writing assistance.

Reference

01. Pirzada U, Tariq H, Azam S, Kumar K, Dev A.

A Rare Cause of Abdominal Pain in Adults: Meckel's Diverticulitis. *Case Rep Gastroenterol.* 2018 Nov 28;12(3):709-714. doi: 10.1159/000494752 [Crossref][PubMed][Google Scholar]

02. Sagar J, Kumar V, Shah DK. Meckel's diverticulum: a systematic review. *J R Soc Med.* 2006 Oct;99(10):501-5. doi: 10.1258/jrsm.99.10.501. Erratum in: *J R Soc Med.* 2007 Feb;100(2):69 [Crossref][PubMed][Google Scholar]

03. Hansen, Carl-Christian, and Kjetil Søreide. "Systematic review of epidemiology, presentation, and management of Meckel's diverticulum in the 21st century. " *Medicine* 97. 35 (2018). [Crossref][PubMed][Google Scholar]

04. Matsukuma Y, Matsuo Y, Sakaguchi M, Yamada T, Hirata T, Tanaka N, et al. A case of siblings with Meckel's diverticulum diagnosed before operation. *Acta Paediatr Jpn.* 1994 Jun;36(3):291-3. doi: 10.1111/j.1442-200x.1994.tb 03183.x [Crossref][PubMed][Google Scholar]

05. Primrose JM, Henry RB. Symptomatic familial Meckel's diverticulum: two case reports and literature review. *S D J Med.* 1977 May;30(5):7-9. [Crossref][PubMed][Google Scholar]

06. Lewenstein HJ, Levenson SS. Familial occurrence of Meckel's diverticulum. *N Engl J Med.* 1963 Feb 7;268:311-2. doi: 10.1056/NEJM196302072680611 [Crossref][PubMed][Google Scholar]

07. Stone PA, Hofeldt MJ, Lohan JA, Kessel JW, Flaherty SK. A rare case of massive gastrointestinal hemorrhage caused by Meckel's diverticulum in a 53-year-old man. *W V Med J.* 2005 Mar-Apr;101(2):64-6. [Crossref][PubMed][Google Scholar]

08. Yorganci K, Ozdemir A, Hamaloglu E, Sokmener C. Perforation of acute calculous Meckel's diverticulitis: a rare cause of acute abdomen in elderly. *Acta Chir Belg.* 2000 Sep-Oct;100(5):226-7. [Crossref][PubMed][Google Scholar]

09. Cserni G. Gastric pathology in Meckel's diverticulum. Review of cases resected between 1965 and 1995. *Am J Clin Pathol.* 1996 Dec;106(6):782-5. doi: 10.1093/ajcp/106.6.782 [Crossref][PubMed][Google Scholar]

10. Ihedioha, U. , Panteleimonitis,

S. , Patel, M. , Duncan, A. , & Finch, G. J. An unusual presentation of Meckel's diverticulum. *Journal of surgical case reports,* 2012.3 (2012): 4-4 [Crossref][PubMed][Google Scholar]

11. Park JJ, Wolff BG, Tollefson MK, Walsh EE, Larson DR. Meckel diverticulum: the Mayo Clinic experience with 1476 patients (1950-2002). *Ann Surg.* 2005 Mar;241(3):529-33. doi: 10.1097/01.sla.0000154270.14308.5f [Crossref][PubMed][Google Scholar]

12. Dumper J, Mackenzie S, Mitchell P, Sutherland F, Quan ML, Mew D. Complications of Meckel's diverticula in adults. *Can J Surg.* 2006 Oct;49(5):353-7. [Crossref][PubMed][Google Scholar]

13. Kusumoto H, Yoshida M, Takahashi I, Anai H, Maehara Y, Sugimachi K. Complications and diagnosis of Meckel's diverticulum in 776 patients. *Am J Surg.* 1992 Oct;164(4):382-3. doi: 10.1016/s0002-9610(05)80909-2 [Crossref][PubMed][Google Scholar]

14. Heinicke JM, Tedaldi R, Muller C. An unusual manifestation of Meckel's diverticulum: bleeding and perforation--a case report. *Swiss Surg.* 1997;3(3):97-9. [Crossref][PubMed][Google Scholar]

15. Wong JH, Suhaili DN, Kok KY. Fish bone perforation of Meckel's diverticulum: a rare event? *Asian J Surg.* 2005 Oct;28(4):295-6. doi: 10.1016/s1015-9584(09)60364-x [Crossref][PubMed][Google Scholar]

16. Tan YM, Zheng ZX. Recurrent torsion of a giant Meckel's diverticulum. *Dig Dis Sci.* 2005 Jul;50(7):1285-7. doi: 10.1007/s10620-005-2774-7 [Crossref][PubMed][Google Scholar]

17. Puligandla PS, Becker L, Driman D, Prokopiw I, Taves D, Davies ET. Inverted Meckel's diverticulum presenting as chronic anemia: case report and literature review. *Can J Surg.* 2001 Dec;44(6):458-9. [Crossref][PubMed][Google Scholar]

18. Soltero MJ, Bill AH. The natural history of Meckel's Diverticulum and its relation to incidental removal. A study of 202 cases of diseased Meckel's Diverticulum found in King County, Washington, over a fifteen year period. *Am J Surg.* 1976 Aug;132(2):168-73. doi: 10.1016/0002-9610(76)90043-x [Crossref][PubMed][Google Scholar]

19. Kusumoto H, Yoshida M, Takahashi I, Anai H, Maehara Y, Sugimachi K. Complications and diagnosis of Meckel's diverticulum in 776 patients. *Am J Surg.* 1992 Oct;164(4):382-3. doi: 10.1016/s0002-9610(05)80909-2 [Crossref][PubMed][Google Scholar]
20. Ymaguchi M, Takeuchi S, Awazu S. Meckel's diverticulum. Investigation of 600 patients in Japanese literature. *Am J Surg.* 1978 Aug;136(2):247-9. doi: 10.1016/0002-9610(78)90238-6 [Crossref][PubMed][Google Scholar]
21. Lorusso R, Forte A, Urbano V, Soda G, D'Urso A, Bosco MR, Mancini P, Bezzi M. I tumori stromali del tenue a localizzazione meckeliana. A proposito di un'osservazione clinica [Small bowel stromal tumors in a "meckelian" location. About a clinical observation]. *Ann Ital Chir.* 2003 Nov-Dec;74(6):707-11. Italian [Crossref][PubMed][Google Scholar]
22. Sutter PM, Canepa MG, Kuhrmeier F, Marx A, Martinoli S. Karzinoidtumor in einem Meckel-Divertikel: Fallvorstellung und Review der Literatur [Carcinoid tumor in Meckel's diverticulum: case presentation and review of the literature]. *Schweiz Med Wochenschr Suppl.* 1997;89:20S-24S. German [Crossref][PubMed][Google Scholar]
23. Stone PA, Hofeldt MJ, Campbell JE, Vedula G, DeLuca JA, Flaherty SK. Meckel diverticulum: ten-year experience in adults. *South Med J.* 2004 Nov;97(11):1038-41. doi: 10.1097/01.SMJ.0000125222.90696.03 [Crossref][PubMed][Google Scholar]
24. Nayak, Biswaranjan, Rashmi Dash, and B. Mallik. Perforated Meckel's diverticulum as a result of gastrointestinal stromal tumor presenting as acute abdomen: A rare case report. *Oncology, Gastroenterology and Hepatology Reports* 4. 1 (2015): 26-26 [Crossref][PubMed][Google Scholar]
25. Parente F, Anderloni A, Zerbi P, Lazzaroni M, Sampietro G, Danelli P, Bianchi Porro G. Intermittent small-bowel obstruction caused by gastric adenocarcinoma in a Meckel's diverticulum. *Gastrointest Endosc.* 2005 Jan;61(1):180-3. doi: 10.1016/s0016-5107(04)02450-2 [Crossref][PubMed][Google Scholar]
26. Hager M, Maier H, Eberwein M, Klingler P, Kolbitsch C, Tiefenthaler W, et
- Al. Perforated Meckel's diverticulum presenting as a gastrointestinal stromal tumor: a case report. *J Gastrointest Surg.* 2005 Jul-Aug;9(6):809-11. doi: 10.1016/j.gassur.2004.12.005 [Crossref][PubMed][Google Scholar]
27. Payne-James JJ, Law NW, Watkins RM. Carcinoid tumour arising in a Meckel's diverticulum. *Postgrad Med J.* 1985 Nov;61(721):1009-11. doi: 10.1136/pgmj.61.721.1009 [Crossref][PubMed][Google Scholar]
28. Dimitriou, I. , Evaggelou, N. , Tavaki, E. , & Chatzitheoklytos, E. *Perforation of Meckel's diverticulum by a fish bone presenting as acute appendicitis: a case report. Journal of medical case reports, 7.1 (2013): 1-4* [Crossref][PubMed][Google Scholar]
29. Chan, Kim W. "Perforation of Meckel's diverticulum caused by a chicken bone: a case report. " *Journal of Medical Case Reports* 3. 1 (2009): 1-2. [Crossref][PubMed][Google Scholar]
30. Ding, Y. , Zhou, Y. , Ji, Z. , Zhang, J. , & Wang, Q. *Laparoscopic management of perforated Meckel's diverticulum in adults. International Journal of Medical Sciences, 9.3 (2012): 243* [Crossref][PubMed][Google Scholar]
31. Shalaby RY, Soliman SM, Fawy M, Samaha A. Laparoscopic management of Meckel's diverticulum in children. *J Pediatr Surg.* 2005 Mar;40(3):562-7. doi: 10.1016/j.jpedsurg.2004.11.032 [Crossref][PubMed][Google Scholar]
32. Chan KW, Lee KH, Mou JW, Cheung ST, Tam YH. Laparoscopic management of complicated Meckel's diverticulum in children: a 10-year review. *Surg Endosc.* 2008 Jun;22(6):1509-12. doi: 10.1007/s00464-008-9832-0 [Crossref][PubMed][Google Scholar]
33. Chan KW, Lee KH, Wong HY, Tsui SY, Wong YS, Pang KY, et al. Laparoscopic excision of Meckel's diverticulum in children: what is the current evidence? *World J Gastroenterol.* 2014 Nov 7;20(41):15158-62. doi: 10.3748/wjg.v20.i41.15158 [Crossref][PubMed][Google Scholar]
34. Mackey WC, Dineen P. A fifty year experience with Meckel's diverticulum. *Surg Gynecol Obstet.* 1983 Jan;156(1):56-64. [Crossref][PubMed][Google Scholar]

35. Önen, A. , Çiğdem, M. K. , Öztürk, H. , Otcu, S., & Dokucu, A. I. When to resect and when not to resect an asymptomatic Meckel's diverticulum: an ongoing challenge. *Pediatric surgery international*, 19.1(2003): 57-61 [Crossref][PubMed][Google Scholar]
36. Robijn J, Sebrechts E, Miserez M. Management of incidentally found Meckel's diverticulum a new approach: resection based on a Risk Score. *Acta Chir Belg.* 2006 Jul-Aug;106(4):467-70. doi: 10.1080/00015458.2006.11679933 [Crossref][PubMed][Google Scholar]
37. Ueberrueck T, Meyer L, Koch A, Hinkel M, Kube R, Gastinger I. The significance of Meckel's diverticulum in appendicitis--a retrospective analysis of 233 cases. *World J Surg.* 2005 Apr;29(4):455-8. doi: 10.1007/s00268-004-7615-x [Crossref][PubMed][Google Scholar]
38. Cullen JJ, Kelly KA, Moir CR, Hodge DO, Zinsmeister AR, Melton LJ 3rd. Surgical management of Meckel's diverticulum. An epidemiologic, population-based study. *Ann Surg.* 1994 Oct;220(4):564-8; discussion 568-9. doi: 10.1097/0000658-199410000-00014 [Crossref][PubMed][Google Scholar]
39. Passarge E, Stevenson RE. Meckel's diverticulum. In: Human malformations and related anomalies, 2nd, Stevenson RE, Hall JE(Eds). Oxford: Oxford University Press; 2006. p. 1111 [Crossref][PubMed][Google Scholar]
40. Michel MI, Field RJ, Ogden WW JR. Meckel's diverticulum; an analysis of one hundred cases and the report of a giant diverticulum and of four cases occurring within the same immediate family. *Ann Surg.* 1955 Jun;141(6):819-29. doi: 10.1097/0000658-195506000-00008 [Crossref][PubMed][Google Scholar]
41. Smith SW, Woodward ER. Peptic ulcer in Meckel's diverticulum; bleeding and perforation in two male siblings. *Ann Surg.* 1955 Dec;142(6):1021-5. doi: 10.1097/0000658-195512000-00022 [Crossref][PubMed][Google Scholar]
42. Abramson DJ. Perforation of Meckel's diverticulum, peritonitis, and intestinal obstruction in the newborn with survival. Meckel's diverticulum in siblings. *Am J Dis Child.* 1960 Aug;10:277-81. doi: 10.1001/archpedi.1960.04020040279018 [Crossref][PubMed][Google Scholar]
43. Patoulias I, Kogia E, Feidantsis T, Michou P, Kalogirou MS, Mitsoulis S, Patoulias DI. Meckel's diverticulum complications in three first-degree relatives: time to rethink familial predisposition? *Prz Gastroenterol.* 2020;15(1):80-81. doi: 10.5114/pg.2020.93634 [Crossref][PubMed][Google Scholar]