

Management of distal femur fractures with locking compression plate

Poptani A¹, Lonikar R²

¹Dr Akshay Poptani, Orthopaedic Surgeon, Gangamai Hospital, Solapur, ²Dr Rushikesh Lonikar, Assistant Professor, Department of Orthopedics, Ashwini Rural Medical College, Hospital and Research Centre, Kumbhari, Solapur, Maharashtra, India.

Address for Correspondence: Dr Rushikesh Lonikar, Row House No. A 8/2, Suncity, Damani Nagar, Solapur, Maharashtra, India. Email: rushikeshlonikar1@gmail.com

Abstract

Background: Distal femur fractures are often caused by high energy trauma mainly sustained in road traffic accidents. Open injuries with considerable comminution of condyles and metaphysis are frequently seen. The present study is undertaken to assess outcome of 20 patients of distal femur fractures treated with locking compression plate. **Methods:** 20 cases of distal femur fractures in adults treated by locking compression plate were studied. Of the 20 'lower end of Femur' fractures, 4 were Mullers type A₃; 2 were Mullers type B₁; 6 were Mullers type C₁; 4 were Mullers type C₂ and remaining 4 were Mullers type C₃. All fractures were closed. Maximum age was 68 years and minimum age was 26 years. 16 were male and 4 were female. Results assessed by time for union, range of motion of knee, shortening, varus/valgus deformity and complications. functional assessment was done by Neers scoring. **Result:** Most common type of distal femur fracture was Mullers type C₁. Of 20 patients, 17 patients (85%) showed radiological union within 18 weeks. Average flexion in this study was 105 degree with more than 65% patients having knee range of motion more than 110 degree. Average extensor lag in this study was 5.60 degrees. 3 had shortening, 2 patients had shortening of 15 mm and 1 had shortening of 10mm. varus / valgus malalignment of less than 5 degree seen in 5 cases. 4 patient developed superficial infection. only one patient went into delayed union. 80 % excellent and good results were obtained by Neers scoring. **Conclusion:** Locking compression plate is an optimal tool for supracondylar fractures of femur. It provides rigid fixation in region of femur, where a widening canal, thin cortices and frequently poor bone stock make fixation difficult. Surgical exposure for plate placement requires significantly less periosteal stripping and soft tissue exposure than that of normal plates.

Keywords: Distal femur fracture, Locking compression plate, trauma

Introduction

The incidence of distal femur fractures is approximately 37 per 1,00,000 person-years [1]. Distal femoral fractures mainly arise from two different injury mechanisms. They are often caused by high energy trauma mainly sustained in road traffic accidents and less commonly by fall from height. Open injuries with considerable comminution of condyles and metaphysis are frequently seen. In high-energy trauma, the problem of restoring the function in a destroyed knee joint persists. In elderly patients, extreme osteoporosis represents a particular problem for anchoring the implant [2].

Distal femur fractures need to be treated operatively to achieve optimal patient outcome. Distal femur fractures can be treated by traditional plating techniques (blade plate, Dynamic Condylar Screw, non-locking condylar

buttress plate), antegrade nailing fixation, retrograde nailing, sub muscular locked internal fixation and external fixation. However, as the complexity of fractures needing treatment has changed from simple extra-articular supracondylar types to inter-condylar and metaphyseal comminuted types, these implants may not be ideal. Double plating, and more recently, locked plating techniques have been advocated. However, with double plating there is often extensive soft tissue stripping on both sides of the femur, resulting in reduced blood supply and potential non-union and failure of the implants [2-4].

The LCP is a single beam construct where the strength of its fixation is equal to the sum of all screw-bone interfaces rather than a single screw's axial stiffness or pullout resistance as seen in unlocked plates. Its unique biomechanical function is based on splinting rather than compression resulting in flexible stabilization, avoidance of stress shielding and induction of callus formation.

Manuscript Received: 10th March 2017
Reviewed: 18th March 2017
Author Corrected: 24th March 2017
Accepted for Publication: 31st March 2017

Further when it is applied via a minimally invasive technique, it allows for prompt healing, lower rates of infection and reduced bone resorption as blood supply is preserved [5].

Internal fixation with locking plates creates a toggle free, fixed angle construct. The introduction of plates with the option of locked screws has provided the means to increase the rigidity of fixation in osteoporotic bone or in the presence of periarticular or juxta-articular fractures with a small epiphyseal segment. The implant offers multiple points of fixed-angle contact between the plate and screws in the distal part of femur, theoretically reducing the tendency for varus collapse that is seen with traditional lateral plates. The DF-LCP is a further development from the LISS which was introduced in the mid to late 1990's. The main difference between the DF-LCP and the LISS is that the LISS utilizes an outrigger device for shaft holes, functioning essentially as a locking guide jig, which is attached to the distal part of the plate and guides the placement of the proximal locking screws. The shaft holes on the DF-LCP are oval allowing for the options of a compression screw or a locking screw. This leads to a more precise placement of the plate, as it is able to be compressed more closely to the bone [2,6].

Material and Methods

Study design- In this study 20 patients with closed supracondylar fractures of femur (distal fifteen cm of femur) were studied. The duration of follow up ranged from 6 months to 12 months. All the fractures in this series were post-traumatic. No pathological fracture was included in the study. Also supracondylar fractures in children were not considered. Supracondylar fractures treated conservatively and fixed with other fixation systems like AO blade plate and condylar buttress plate were not included.

Setting- The following protocol was observed for patients with fracture lower end of femur on arrival.

1. General and systemic examination as well as local examination of the patient.
2. Thorough assessment of patient to rule out head/ chest/ abdominal/ spinal or pelvic injury.
3. Evaluation of patients in terms of:
 - a) age
 - b) Sex
 - c) Mode of trauma
 - d) Period between injury and arrival.
4. Musculo-skeletal examination of patient to rule out associated fractures.
5. Stabilization of patient with intravenous fluids, oxygen and blood transfusion as and when required.

6. Careful assessment of injured limb as regards to neurovascular status.
7. Primary immobilization of involved limb in Thomas splint with a cotton pad below the distal fragment and transport of patient to the Department of Radiodiagnosis in the same.
8. Radiological assessment: Antero-posterior and true lateral views of injured limb including complete knee joint and distal femur/proximal leg.
9. Fractures were classified according to Mullers (AO) classification[7]
10. Thorough irrigation and lavage of associated compound injuries with hydrogen peroxide and normal saline followed by Povidone Iodine padded dressings.
11. Upper Tibial skeletal pin traction with a Steinmann or Derham pin drilled under local anesthesia followed by continuous traction given over the Bohler Braun splint was used
12. Compound fractures were not considered in the study.
13. Injection ATS 1500 IU, Injection AGGS 20,000 IU, broad spectrum injectable antibiotics and analgesics were administered for compound injuries of other parts as and when required.

Patient Selection

- a) All types of fracture lower end of femur (AO classification A, B & C).
- b) Only closed fractures were considered.
- c) Paediatric patients and pathological fractures excluded.

Inclusion criteria

- a) Those patients who are above the age of 20 yrs and managed surgically were included in the study
- b) Patients presenting with distal femoral fractures with or without osteoporotic changes were included in the study

Exclusion criteria

1. Patients with open distal femoral fractures
2. Children with distal femoral fractures in whom, growth plate is still open.
3. Patients lost in follow – up
4. Patients managed conservatively for other medical reasons.
5. Distal femoral fractures with neurovascular compromise

Data source - All the cases were treated at Gangamai hospital, Solapur, between 01-10-2014 & 01-12-2015 and followed for a minimum of 6 months.

Study size- 20 patients of closed distal femur fracture.

Implant used: The plate and screws are manufactured from 316L stainless alloy with gun drilling technique. The locking compression plates are available from 8 holed to 14 holed With 4.5 mm thickness plate for lower end of femur. These are anatomically precontoured plate head with soft edges. LCP have combi-holes in the plate shaft for intraoperative choice between angular stability and/or

compression. LCP have 50° of longitudinal screw angulation and 14° of transverse screw angulation with uniform hole spacing. 4.0 mm and 5.00 mm self tapping locking screws with 3.2mm and 4.3mm drill bits respectively along with threaded drill sleeves are available.

Results

In this study, maximum age was 68 years and minimum age was 22 years. Mean age was 44 years. There was male (80%) predominance in our study. Most common nature of violence was road traffic accidents (75%) followed by fall from height (25%) Of the 20 'lower end of Femur' fractures, 4 were Mullers type A₃; 2 were Mullers type B₁; 6 were Mullers type C₁; 4 were Mullers type C₂ and remaining 4 were Mullers type C₃. All fractures were closed.

Table-1: Type of fracture according to Mullers classification.

Supracondylar	No of Patients
MULLERS A1	NIL
MULLERS A2	NIL
MULLERS A3	4
MULLERS B1	2
MULLERS B2	NIL
MULLERS B3	NIL
MULLERS C1	6
MULLERS C2	4
MULLERS C3	4

8 patients had associated injuries. Of them, 2 patients had comminuted fractures of contralateral tibia. 2 patients among fracture lower end femur pattern has ipsilateral tibial fracture and 2 patient has fractures of the acetabulum one patient has associated distal end radius fracture and one patient had fracture of patella ipsilateral side. All patients were operated within 7 days. 5 of them operated within 3 days of injury. Average time duration of surgery was 123 minutes.

The size of plate was selected based on the type of fracture. Ten to Twelve holed plates were used more commonly. Of 20 patients, 17 patients (85%) showed radiological union within 18 weeks. One patient went for delayed union. Infection was encountered in 4 case. They were early infections treated with saline wash, Debridement and higher antibiotics as warranted by culture report. The fractures went on to heal uneventfully.

Average flexion in this study was 105 degree with more than 65% patients, 3 had shortening, 2 of them shortening of 15mm and 1 patient had shortening of 10mm. In this study, very few patients had significant varus / valgus malalignment. The duration of follow-up ranged from 4 months to 12 months.

Table-2: Radiological Union.

Union (weeks)	No. of cases
<16	8
16-18	9
19-20	2
21-22	Nil
Delayed union	1
Non union	0

Radiological union was defined as presence of bridging callus across three cortices. Of 20 patients, 17 patients (85%) showed radiological union within 18 weeks.

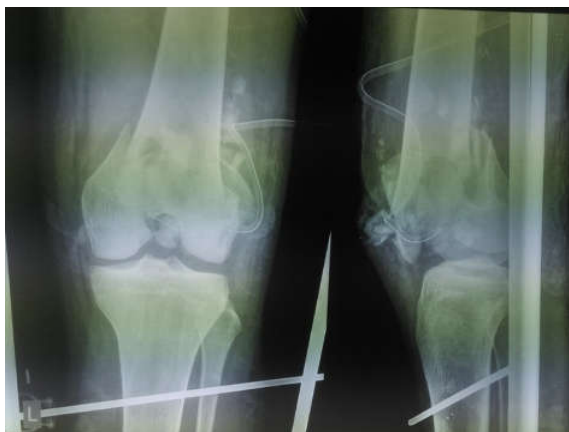

Figure-1: Preoperative x ray

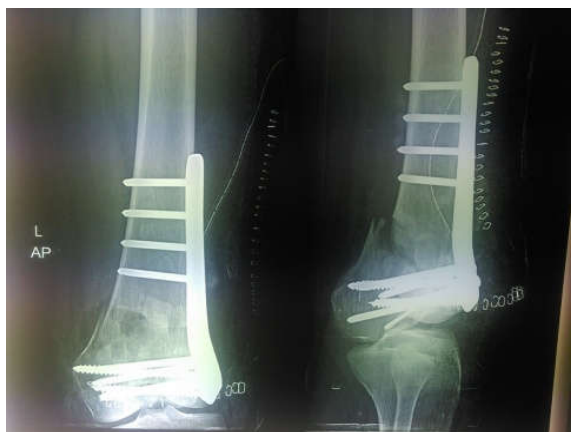

Figure 2: immediate post operative x ray

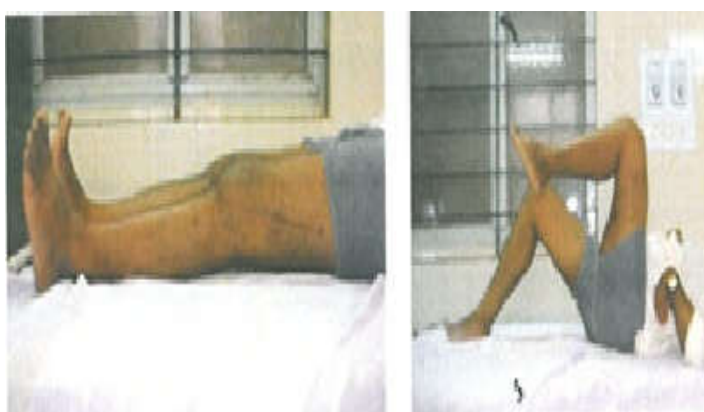
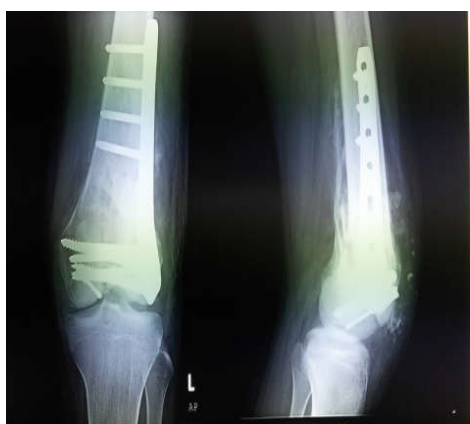

Figure-3 and 4: 18 weeks follow up showing radiological union and range of motion.

Table- 3: Complications.

Complications	No. of cases
Superficial infection	4
Delayed union	1
Plate backout	Nil
Deep infection	Nil
Non-union	0
Implant failure – screw/plate breakage	0
Stress fracture	0

Table-4: Functional outcome by Neers scoring.

Grade	No. of cases
Excellent	11
Good	5
Fair	3
Poor	1

Discussion

Our study comprised of twenty patients with distal end Femur Fractures who were treated by Locking Condylar Buttress plate. Overall final outcome was assessed in terms of regaining the lost knee using NEER'S Score. In a study by Schutz M, Muller M et al[4] , internal fixation using the LISS was performed at an average of 5 days (range: 0-29 days) after the injury. 48 fractures were operated on within the first 24 hours. Revision operations were required for 2 cases of implant breakage. 4 cases of implant loosening and 7 debridement's to deal with infections. The study showed clearly that when working with LISS, primary cancellous bone grafting was not necessary. The total follow up rate was 93%. Non union was observed in 5% cases.

Our results are comparable to the study with similar rates of infection although no cases of implant breakages and non union were seen. And since open reduction was done in all cases bone grafting was preferred unless in cases of simple metaphyseal fractures like Mullers A1. Weight and Collinge [8] retrospectively evaluated the use of the LISS locked plating construct in 22 distal femur fractures in 21 patients. All fractures achieved union at a mean of 13 weeks (range, 7 to 16 weeks) without the need for secondary intervention. There was no implant failure in this patient cohort: at a mean of 19 months of follow-up, knee range of motion was 5 to 114 degrees.

In a similar retrospective evaluation of LISS plate fixation for 103 distal femur fractures, Kregor et al[9] reported a 93% union rate without secondary bone grafting. The remaining 7 cases went on to uneventful union subsequent to bone grafting procedures. At a mean follow – up of 14 months, the mean Knee range of motion in this cohort was 1 to 109 degrees. Implant failure in the form of proximal screw loosening occurred in 5 cases, each requiring revision surgery. In our study average time for union is slightly more when compared to the above studies this may be in accordance with the fact that all our cases treated with open reduction with incidence of infection (superficial) which is higher since we used open reduction and internal fixation, in about four cases and the relatively higher incidence of associated fractures in eight cases.

Table-5: Distal femur comparison studies.

Study	No of cases	Mean follow – up	Average Union time	Implant failure
Weight and Collinges	22	19 months	13 weeks	None
Kregor et al	103	14 months	12weeks	5
Yeap and Deepak	11	9.7 months	18 weeks	1
Present study	20	8 months	18 weeks	None

Yeap, E.J., and Deepak, A.S [10] conducted a retrospective review on eleven patients who were treated for Type A and C distal femoral fractures (based on AO classification) between January 2004 and December 2004. All fractures were fixed with titanium distal femoral locking compression plate. The patient's ages ranged from 15 to 85 with a mean of 44. Clinical assessment was conducted at least 6 months post- operatively using the Schatzker score system. Results showed that four patients had excellent results, four good, two fair and one failure.

Zlowodzi et al[9] combine these series (n=327) and evaluated the outcomes as part of a systematic literature review. Average nonunion, fixation failure, deep infection, and secondary surgery rates were 5.5%, 4.9%, 2.1% and 16.2% respectively. Some of the technical errors that have been reported for fixation failure have involved waiting too long to bone graft defects, allowing early weight bearing, and placing the plate too anterior on the femoral shaft.

Vallier et al [11] in his study concluded that locking plates should only be used when conventional fixed – angle devices cannot be placed. They noted the significant added cost of locking plates. To decrease the risk of implant failure with locking plates, they recommended accurate fracture reduction and fixation along with judicious bone grafting, protected weight bearing, and modifications of the implant design. In our study, outcome in the form regaining the lost knee function is assessed using NEER'S Score. In 20 fractures around knee, 11 patients showed excellent result. 5 Patients showed good outcome 4 patients fair and 1 patient showed poor result. In our study functional results are close to the functional results achieved in other studies so are the rate of complications. We had one case of delayed union. On analyzing it retrospectively we believe the reason for delayed union was due to technical reasons, with inappropriate use of locking screw at places where compression through plain screws should have been used.

Conclusion

Locking compression plate is a good fixation system for distal end femoral fracture particularly intra-articular type. Operative time is certainly reduced when working with Locking Compression plate since surgical dissection is kept to a minimum. The device provides good angular stability by its triangular reconstruction principle and thus helps in early mobilization, even in comminuted fractures where other modes of fixation often tend to delay the process of mobilization because of lack of stability. Perhaps one of its greatest applications, is in osteoporotic fractures where it may provide a solution to the age old problems of screw cut out, late collapse, and malalignment. Basic principles of fixation and the appropriate indications for use of LCP in fractures of distal end femur is a must, before its use. It provides rigid fixation in region of femur, where a widening canal, thin cortices and frequently poor bone stock make fixation difficult. Surgical exposure for plate placement requires significantly less periosteal stripping and soft tissue exposure than that of normal plates.

However careful understanding of its basic principles, identification of appropriate fracture pattern for use of LCP is essential to avoid complications like generation of non union.

To conclude, **Locking Compression Plate** is an important armamentarium in treatment of fracture of distal end femur, especially when fracture is severely comminuted and in situations of osteoporosis. However a more comprehensive study with longer follow up periods is essential to throw more light into advantages, complications and possible disadvantages of the use of Locking Plate with special attention to the long term outcomes.

Conflict of interest: None declared.

Funding: Nil, **Permission from IRB:** Yes

References

1. Arneson TJ, Melton LJ 3rd, Lewallen DG, O'Fallon WM. Epidemiology of diaphyseal and distal femoral fractures in Rochester, Minnesota, 1965-1984. *Clin Orthop Relat Res.* 1988 Sep;(234):188-94.
2. Schandelmaier P, Partenheimer A, Koenemann B, Grün OA, Krettek C. Distal femoral fractures and LISS stabilization. *Injury.* 2001 Dec; 32 Suppl 3:SC55-63.
3. Kregor PJ, Stannard J, Zlowodzki M, Cole PA, Alonso J. Distal femoral fracture fixation utilizing the Less Invasive Stabilization System (L.I.S.S.): the technique and early results. *Injury.* 2001 Dec;32 Suppl 3:SC32-47.
4. Schütz M, Müller M, Regazzoni P, Höntzsch D, Krettek C, Van der Werken C, Haas N. Use of the less invasive stabilization system (LISS) in patients with distal femoral (AO33) fractures: a prospective multicenter study. *Arch Orthop Trauma Surg.* 2005 Mar;125(2):102-8. Epub 2005 Feb 2.
5. Kregor PJ, Stannard JA, Zlowodzki M, Cole PA. Treatment of distal femur fractures using the less invasive stabilization system: surgical experience and early clinical results in 103 fractures. *J Orthop Trauma.* 2004 Sep; 18(8):509-20.
6. Martinet O, Cordey J, Harder Y, Maier A, Bühler M, Barraud GE. The epidemiology of fractures of the distal femur. *Injury.* 2000 Sep;31 Suppl 3:C62-3.
7. Muller ME, Nazarian S, Koch P, Sdiatzker J. The comprehensive classification of fractures of long bones. Berlin, etc : Springer-Verlag, 1990.
8. Weight M, Collinge C. Early results of the less invasive stabilization system for mechanically unstable fractures of the distal femur (AO/OTA types A2, A3, C2, and C3). *J Orthop Trauma.* 2004; 18:503-508.
9. Kregor PJ, Stannard JA, Zlowodzki M, et al. treatment of Distal Femur Fractures Using the Less Invasive Stabilization System: Surgical Experience and Early Clinical Results in 103 fractures. *J Orthop Trauma* 2004 sep;18(8):509-20.
10. Yeap, E.J., and Deepak, A.S., Distal Femoral Locking Compression Plate Fixation in Distal Femoral Fractures: Early Results. *Malaysian Orthopedic Journal*, 2007; 1 (1). Pp. 12-17. ISSN 1985-2533.
11. Vallier HA, Hennessey TA, Sontich JK, Patterson BM. Failure of LCP condylar plate fixation in the distal part of the femur. A report of six cases. *J Bone Joint Surg Am.* 2006 Apr;88(4):846-53.

How to cite this article?

Poptani A, Lonikar R. Management of distal femur fractures with locking compression plate. *Int J surg Orthopedics* 2017;3(1):6-11.doi:10.17511/ijoso.2017.i01.02.