

Study of incisional hernia with onlay mesh repair

Khan R.^{1*}, Singh K.²


DOI: <https://doi.org/10.17511/ijoso.2020.i03.06>

^{1*} Rafat Khan, Resident, Department of General Surgery, Peoples College of Medical Sciences and Research Centre, Bhopal, Madhya Pradesh, India.

² Kulwant Singh, Associate Professor, Department of General Surgery, Peoples College of Medical Sciences and Research Centre, Bhopal, Madhya Pradesh, India.

Background: Any abdominal wall gap with or without a bulge in the area of a postoperative scar perceptible or palpable by clinical examination or imaging is defined as an incisional hernia. The present work was thus planned to study an incisional hernia and to evaluate the outcome of onlay mesh repair with reference to a technical difficulty, complication rate, and recurrence. **Methods:** The study was conducted on all patients of primary incisional hernia above 18 years with the previous history of abdominal surgery and admitted for the treatment of an incisional hernia from November 2017 to April 2019. **Results:** Majority of patients are in a group of 51-60 years, youngest was 22 year and oldest was 69 year with a mean age of 48.6 years, with female to male ratio 5:3, most common symptom was swelling in the abdomen, 44% with irreducible swelling while 56% with reducible swelling in the abdomen, 75% with lower and 25% with upper abdomen swelling, about 6% with incisional hernia between 1-2 years of previous surgery, total 94% after 2 years of previous surgery, 44% of incisional hernias occurred below the umbilicus in the midline. Laparotomy was the most common surgery causing hernia followed by LSCS, 63% patient had hernia defect of size 1-5cm, 31% had 5-10cm, and the remaining 6% had more than 10 cm. **Conclusion:** For a short learning period for surgeons, the Onlay technique is a simple and effective repair, complications, and recurrence rates show to be apparently safe and require minor tissue dissection with an easy approach to the hernia repair.

Keywords: Incisional hernia, Onlay mesh, Complications, Recurrence

Corresponding Author	How to Cite this Article	To Browse
Rafat Khan, Resident, Department of General Surgery, Peoples College of Medical Sciences & Research Centre, Bhopal, Madhya Pradesh, India. Email: rafatkhan80@gmail.com	Khan R, Singh K. Study of incisional hernia with onlay mesh repair. <i>Surgical Rev Int J Surg Trauma Orthoped.</i> 2020;6(3):173-180. Available From https://surgical.medresearch.in/index.php/ijoso/article/view/187	

Manuscript Received 2020-06-10	Review Round 1 2020-06-20	Review Round 2 2020-06-25	Review Round 3	Accepted 2020-06-29
Conflict of Interest No	Funding Nil	Ethical Approval Yes	Plagiarism X-checker 8%	Note

© 2020 by Rafat Khan, Kulwant Singh and Published by Siddharth Health Research and Social Welfare Society. This is an Open Access article licensed under a Creative Commons Attribution 4.0 International License <https://creativecommons.org/licenses/by/4.0/> unported [CC BY 4.0].




Introduction

Any abdominal wall gap with or without a bulge in the area of a postoperative scar perceptible or palpable by clinical examination or imaging is defined as an incisional hernia [1]. By other definitions, it is considered as a breakdown or loss of continuity of fascial closure. An incisional hernia is a diffuse migration of peritoneum and abdominal contents through a weak scar of operation or accidental wound as defines by Ian Aird.

Incisional hernias are a result of inadequate healing of a previous incision and excessive tension, which is often associated with surgical site infection, enlarge overtime of a period, causes pain, bowel obstruction, incarceration, and strangulation. The predisposing factors to the development of an incisional hernia are obesity, advanced age, malnutrition, ascites, pregnancy, and conditions that increase intra-abdominal pressure [1].

An incisional hernia occurs in 5-11% of patients subjected to abdominal operations [2,3]. Within the first 2 years after primary surgery more than 50% of incisional hernias present [4,5]. Many years of attempts have been made to develop successful methods for repairing incisional hernia from anatomical repair to laparoscopy, but most attempts were followed by a high incidence of complications and recurrence.

The complications of repairing an incisional hernia which should be explained to the patient when obtaining consent include seroma formation, wound infection, recurrence, and injury to intraabdominal structures [6]. Prosthetics has revolutionized the hernia surgery with the concept of tension-free repair. Mesh repair technique showed a decreased number of postoperative complications and recurrence compared to other techniques [7].

Material and Methods

Study Settings:

Study-type: Hospital-based Prospective Observational Study

Duration of study: 1 year (November 2017 to April 2019)

Study area: The study was conducted on patients admitted to the People's College of Medical Sciences and Research Centre, Bhopal for the treatment of an incisional hernia.

Sampling method: Purposive sampling method (Consecutive type of non-probability sampling technique)

Sample size calculation: A total of 32 consecutive patients of incisional hernia, admitted in our hospital and satisfying the eligibility criteria were taken in the study after informed consent

Inclusion criteria: All patients of primary incisional hernia with the previous history of abdominal surgery who attended surgery OPD.

Exclusion criteria

01. Age less than 18 years.
02. Polypropylene mesh was laid over the closed defect. An appropriate size of the mesh was selected depending on the size of the defect.
03. Patient with a strangulated hernia.
04. Patient with intraabdominal malignancy.
05. Laparoscopic surgery.

Data collection procedure: Consecutive type of non-probability sampling was used for the selection of study subjects. A total of 32 consecutive patients of Incisional hernia, admitted in our hospital and satisfying the eligibility criteria were taken in the study after informed consent.

Surgical procedure: Adhesions were released and a simple reposition of the contents into the abdominal cavity was done. Following materials were used:

01. Round body needle Proline no.2 was used to close the rectus sheath
02. Polypropylene mesh was laid over the closed defect. An appropriate size of the mesh was selected depending on the size of the defect.
03. Prolene suture no. 2-0 with a round body needle was used to fix the mesh to the anterior abdominal wall.
04. Plain Catgut i.e. absorbable suture material used to close the subcutaneous fat.
05. Closed suction drain tubes with continuous suction over the mesh were used in all the cases.

Statistical Analysis: Data was compiled using MS Excel and analyzed using SPSS software version 20. A P-value of less than 0.5 was considered significant and a p-value of less than 0.01 was considered highly significant.

Results

Table-1: Age-wise distribution of study subjects.

Age group	No of case	Percentage
20-30 year	1	3%
31-40 year	6	19%
41-50 year	9	28%
51-60year	11	34%
61-70 year	5	16%
Total	32	100%

This table shows that the majority of patients are in a group of 51-60 years.

In the study, the youngest patient was 22 years old and oldest was 69 years old with a mean age of 48.6 years

Table-2: Sex incidence of incisional hernia.

Sex	No. of case	Percentage
Male	12	37%
Female	20	63%
Total	32	100%

This study shows that the incidence of incision hernia is more common in females than males with female to male ratio of 5/3.

Table-3: Clinical presentation of cases.

Clinical presentation	No of cases	Percentage
Reducible Swelling	18	56%
Irreducible Swelling	14	44%

In the present study, the most common symptom that patients presented with was swelling in the abdomen.

56% of patients had associated with reducible swelling and 44% with irreducible swelling in the abdomen.

Table-4: Distribution of swelling.

Position of swelling	No of cases	Percentage
Upper abdomen	8	25%
Lower abdomen	24	75%
Total	32	100%

In the present study, 75% of patients presented with lower abdomen swelling, and 25% of patients presented with upper abdomen swelling.

Table-5: Time of onset of incisional hernia after previous surgery.

Time of onset	No. of cases	Percentage
Within 1 year	0	0%

1 -2 years	2	6%
2-5 years	15	47%
More than 5 years	15	47%

From the above data, it is found that none of the patients presented with incisional hernia within one year of previous surgery.

6% of patients presented between 1-2 years. A total of 94% of patients present after 2 years of previous surgery.

Table-6: Nature and types of incisions of previous surgery.

Lower midline	Hysterectomy	7
	Tubectomy	1
	Laparotomy	3
	Complicated Appendectomy	3
Rt. paramedian	Laparotomy	2
Pfannenstiel	LSCS	8
Rt. Lumber	Right nephrectomy	1
Kocher/Sub coastal	Open cholecystectomy	3
Upper midline	Laparotomy	4

From the above table, it is found that in the present study, 44% of incisional hernias occurred below the umbilicus in the midline. Laparotomy was the most common operation causing hernia followed by LSCS.

Table-7: Size of the hernial defect (detected by usg).

Size in diameter	No.	%
1-5cm	20	63%
5 - 10cm	10	31%
More than 10cm	2	6%
Total	32	100%

This table shows that 63% of patients had hernia defect of size 1-5cm. Another 31% had a defect of 5-10cm. Remaining 6% had a defect of more than 10 cm.

Operative Findings

Table-8: Duration of surgery (min).

Surgery time	N	%
1-2 Hour	22	69%
2-3 Hour	8	25%
3-4 Hour	2	6%
Total	32	100%

01. Duration of surgery varied with each case, the average time is taken for surgery in

02. 69% of patients is about 1-2 hour.

03. No technical difficulty was encountered in performing onlay mesh repair.

Table-9: Post-operative complications.

Complications	N	Percentage
Seroma	3	9%
Surgical site infection	Superficial-1	3%
	Deep-1	3%
Skin necrosis	1	3%
Fistula	0	0%

In the present study, 6 patients had postoperative complications. The most common complications were seroma, which occurred in 9% of cases.

Tabel-10: Time is taken to resume normal activities or convalescence period.

Days	N	%
1-2 weeks	0	0%
2-3 weeks	20	63%
> 3 weeks	12	37%
Total	32	100%

In the present study, the convalescence period in 63% of patients was between 14 to 21 days, where 37% of patients were more than 21 days.

Tabel-11: Period of follow up and recurrence.

Recurrence in 6 months	N	%
Yes	0	0%
No	32	100%
Total	32	100%

Followed up for 6 months period were done in all the 32 cases and no recurrence was noted

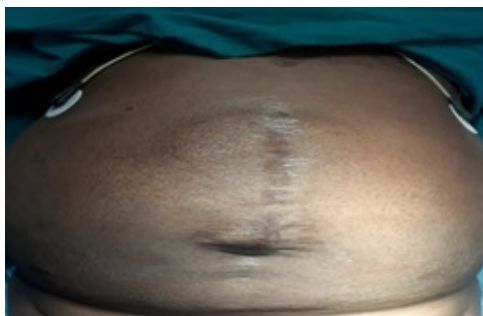

Fig-1: Incisional hernia.

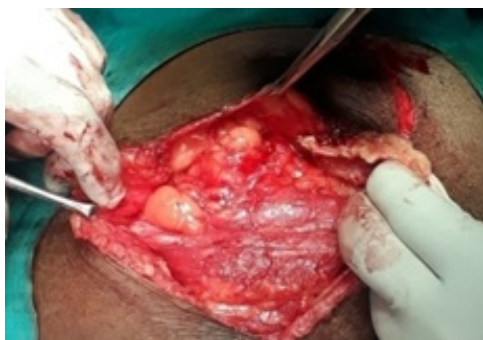

Fig-2: After reduction of the hernial sac.

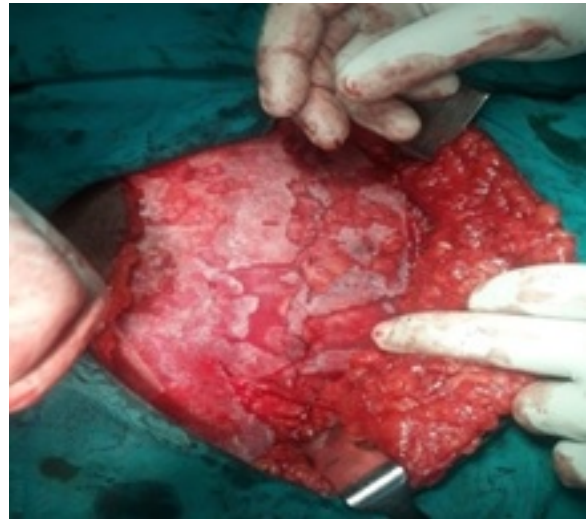


Fig-3: Mesh fixed over the defect.

Discussion

A hospital-based prospective observational study was conducted with the aim of studying the clinical profile of patients with an incisional hernia. The present study also evaluated the outcome of onlay mesh repair with respect to postoperative complications, technical difficulty, and recurrence.

Demographic characteristics: The majority of patients are in the group of 51 -60 years with a mean age of 48.6 years. The female to male ratio of 5:3.

In Narayanswamy et al study. [9], Incisional hernia was more often in 31-40 years age group and mainly in females. In a study of Manohar et al. [10], the observed age distribution of the 50 Incisional hernia cases ranged from 25 years to 70 years (male, n= 6 / female, n= 44) with peak incidence 31-40 age group, with female preponderance seen.

In a study by Nanjappa et al. [11], there were 7 males (23.3%) and 23 females (76.7%) and the highest incidence was in the 5th decade and the mean age was 43.63 years. Jyothirmayi et al. study [12] also observed the mean age as 38 years with a female predominance. The mean age of patients in a study by Memon A et al. [13] was 43.8 ± 11.8 with female preponderance (male: female; 1:1.6).

Clinical history and examination: In the present study most common symptom that patients presented with was swelling in the abdomen in which 56% of patients had associated with reducible swelling while 44% of patients had associated with irreducible swelling with pain. A total of 6% of

Patients present within 2years of previous surgery while most patients (94%) present after 2 years of previous surgery.

In Narayanswamy et al. study [9], out of 100 patients, 81 patients presented with pain, and 88% of patients had swelling at the end of 5years.

In Manohar et al [10] study, all 50 patients came with a history of swelling in which 36% cases also had a history of pain and 30% cases had early onset of incisional hernia (< 1 year), rest 70% of cases had late onset of incisional hernia more than 1 year. In a study of Nanjappa et al. [11], observed 13 patients (43.33%) complained of a lower midline swelling.

Size of defect: A total of 63% of patients had hernia defect of size 1-5 cm. Another 31% had a defect of 5-10cm. In a study by Narayanswamy et al. [9], the size of the defect was less than 3 cm in 41% of patients. In a study by Nanjappa et al. [11], a total of 53% of patients had hernia defect of size 1-5cm. In 43% of cases of Memon A et al. series [13], the defect size was between 1-5 cm [83].

Type of incision and surgery: A total of 75% of patients had previous surgeries through lower abdominal incisions. Out of 32 patients, 14 had lower midline incision (44%), 8 had Pfannenstiel incision, 4 patients had upper midline incision, 2 patients with a right paramedian incision, 3 patients with Kocher/subcoastal incision, 1 patient with a right lumbar incision. Laparotomy was the most common operation causing hernia followed by LSCS.

In a study of Narayanswamy et al. [9], out of 100 cases, 15 patients had previous surgeries through right paramedian incisions, 8 with left paramedian incision, 59 with a lower abdominal incision, 13 with an upper midline incision and 5 with Mc Burneys.

Out of 59 patients who had lower abdominal incisions, 9 cases had undergone recurrent incisional hernia repair, 21 cases had undergone Caesarian section, 15 cases- Abdominal hysterectomy, 10 cases- tubectomy, 4 patient had undergone laparotomy.

Manohar et al. [10] also observed 78% of cases following obstetric and gynecological operations. Of 50 cases, 74% of cases had surgery through a lower midline incision. Nanjappa et al. [11] also observed 21 (70%) patients had lower abdominal incisions in the index surgery and 9 (30%) had upper abdominal incisions.

A total of 63.3% of cases occurred following obstetric and gynecological operations. In the study by Jyothirmayi et al. [12], 80% incisional hernias observed in sub umbilical midline incisions.

Midline incisions developed an incisional hernia in 75% of cases in a study by Parekh et al. [14]. A lower midline incision is generally more prone to herniation as posterior rectus sheath is deficient below the umbilicus.

Present surgery details: Duration of surgery varied with each case, the average time is taken for surgery in 69% of patients is about 1-2 hours. No technical difficulty was encountered in performing onlay mesh repair. The contents of the sac were either the small intestine or omentum or both. In 20 cases adhered omentum which was devitalized after releasing had to be excised partly.

Complications: In the present study, six (6) patients had postoperative complications. The most common complications were seroma, which occurred in 9% of cases followed by surgical site infection (6%).

The convalescence period in 63% of patients was between 14 to 21 days, whereas 37% of patients were more than 21 days. In a Manohar et al. study [8], Only 2% had wound infection, 10% seroma, and 2% DVT. No postoperative complications were found in 86% of cases. In a Machiras A et al. study observed wound infection in 7% cases while seroma formation in 14% cases [15].

Tabel-12: Comparison of the complications in the present study with previously conducted studies.

Complication	Present study	Kingsnorth et al [17]	Burger et al [19]	Anderson et al. [18]
Wound Infections	6 (6%)	2 (1.7%)	7%	2(3.6%)
Seroma	3 (9%)	11 (9.5%)	10%	3(5.3%)
Fistula	0%	0%	0%	0%

Recurrence: All the 32 cases were followed up for a period of 6 months and no recurrence was noted. Manohar et al. observed no recurrence in 50 cases at the end of 2 years follow up.

In a study by Memona A et al. [13], (6.67%) patients had a recurrence of a hernia within 1 year. Machiras A et al. [15] observed recurrence in 9% of cases managed by onlay mesh repair.

Antonie Hamy et al reported a recurrence rate of incisional hernia following mesh repair with 3.1% of cases [16].

Limitations

Small sample size. Non-probability criteria sampling has limitations for the generalizability of the study findings. Due to inadequate sample size, there is a need for further study with adequate size to get the desired outcome.

Conclusion

A lower abdominal midline incision was the major predisposing factor for [incisional hernia [IH]. For a short learning period for the surgeon, the Onlay technique is a simple and effective repair operation. The present study in terms of complications and recurrence rates for the patient shows that the Onlay technique to be apparent safe. Also, in addition, this technique requires minor tissue dissection with an easy approach to the hernia repair. These benefits should be taken into consideration when selecting between laparoscopic and open technique and when selecting between different open techniques.

What does the study add to the existing knowledge?

Based on findings, it is concluded that onlay mesh repair for incisional hernia is an effective approach, no technical difficulty was encountered in performing onlay mesh repair, takes an average duration of two hours to perform with a shorter convalescent period for patients and minimal post-operative complications with no recurrence in 6 months follow up. Thus it is one of the best operations for repairing an incisional hernia. This study evaluated the outcome of onlay mesh repair with respect to postoperative complications, technical difficulty, and recurrence.

Author's contribution

Dr. Rafat Khan: Concept, study design, manuscript preparation

Dr. Kulwant Singh: Manuscript preparation

Reference

01. Korenkov M, Paul A, Sauerland S, Neugebauer E, Arndt M, Chevrel JP, et al. Classification and surgical treatment of incisional hernia, Results of an experts' meeting. *Langenbecks Arch Surg.* 2001;386(1)65-73.
doi: [Article] [Crossref]
02. George CD, Ellis H. The results of incisional hernia repair- a twelve year review. *Ann R Coll Surg Engl.* 1986;68(4)185-187.
[Crossref]
03. Mudge M, Hughes LE. Incisional hernia- a 10 year prospective study of incidence and attitudes. *Br J Surg.* 1985;72(1)70-71.
doi: [Article] [Crossref]
04. Cuschieri A, Steele RJC, Moossa AR, eds. *Incisional Hernia, In essential Surgical Practice, 4th ed.* New York. 2002;169.
[Crossref]
05. Bessa SS, Katri KM, Abdel-Salam WN, Abdel-Baki NA. Early results from the use of the Lichtenstein repair in the management of strangulated groin hernia. *Hernia.* 2007;11(3)239-242.
doi: [Article] [Crossref]
06. Society for Surgery of the Alimentary Tract. Guidelines- Surgical repair of incisional hernias. *J Gastrointest Surg.* 2004;8;369-370.
doi: [Article] [Crossref]
07. Kingsnorth A. The management of incisional hernia. *Ann R Coll Surg Engl.* 2006;88(3)252-260.
doi: [Article] [Crossref]
08. Othman IH, Metwally YH, Bakr IS, Amer YA, Gaber MB, Elgohary SA. Comparative study between laparoscopic and open repair of a paraumbilical hernia. *J Egypt Soc Parasitol.* 2012;42(1)175-182.
doi: [Article] [Crossref]
09. Narayanaswamy T, Venugopal K, Nikshita N. Clinical study and management of incisional hernias- our experience. *J Evo Med Den Sci.* 2013;47(2)9112-9118.
[Crossref]
10. Manohar CS, Ramadev K. Management of incisional hernia by preperitoneal mesh repair. *Int J Basic Med Sci.* 2010;1(3)12-19.
doi: [Crossref]
11. Nanjappa BA, Mohanty A, Smile SR. Incisional hernia repair-a clinical study of 30 patients. *Int J Current Res and Rev.* 2013;5(15)35-41.
[Crossref]
12. Jyothirmayi K, Ravitheja A, Reddy PC, Dushyanth. Clinical study and management of incisional hernia. *J Evid Based Med Health.* 2016; 3(36)1745-1748.
doi: [Article] [Crossref]

13. Memon AA, Khan A, Zafar H, Murtaza G, Zaidi M. Repair of large and giant incisional hernia with onlay mesh- a perspective of a tertiary care hospital of a developing country. *Int J Surg.* 2013;11(1)41-45.
doi: [Article] [Crossref]
14. Parekh JN, Shah DB, Thakore AB. Incisional hernia- a study of 76 cases. *Ind J Surg.* 1988;50;49-53.
[Crossref]
15. Machairas A, Misiakos EP, Liakakos T, Karatzas G. Incisional hernioplasty with Extraperitoneal onlay polyester mesh. *Am J Surg.* 2004 ;70(8)726-729.
[Crossref]
16. Hamy A, Pessaux P, Mucci-Hennekinne S, Radriamananjo S, Regenet N, Arnaud JP. Surgical treatment of large incisional hernias by an intraperitoneal Dacron mesh and an aponeurotic graft. *J Am Coll Surg.* 2003;196(4)531-534.
doi: [Article] [Crossref]
17. Kingsnorth AN, Shahid MK, Valliatter AJ, Hadden RA, Porter CS. Open onlay mesh repair for major abdominal wall hernias with selective use of components separation and fibrin sealant. *World J Surg.* 2008;32(1)26-30.
doi: [Article] [Crossref]
18. Andersen LP, Klein M, Gögenur I, Rosenberg J. Long-term recurrence and complication rates after incisional hernia repair with the open onlay technique. *BMC Surg.* 2009;9;6.
doi: [Article] [Crossref]
19. Burger JW, Luijendijk RW, Hop WC, Halm JA, Verdaasdonk EG, Jeekel J. Long-term follow-up of a randomized controlled trial of suture versus mesh repair of incisional hernia. *Ann Surg.* 2004;240(4)575-578.
doi: [Article] [Crossref]